

RESEARCH ARTICLE

β -Carotene patch application effects on gingival crevicular fluid volume after panoramic radiography exposure

Anggun Dwi Andini*, Rini Widyaningrum**, Rurie Ratna Shantiningsih**✉

*Dentistry Study Program, Faculty of Dentistry, Universitas Gadjah Mada, Yogyakarta, Indonesia

**Department of Dentomaxillofacial Radiology, Faculty of Dentistry, Universitas Gadjah Mada, Yogyakarta, Indonesia

**Jl Denta No 1, Sekip Utara, Yogyakarta, Indonesia; ✉ correspondence: rurieratna@ugm.ac.id

Submitted: 25th May 2018; Revised: 8th January 2019; Accepted: 8th February 2019

ABSTRACT

Panoramic radiography is a radiography technique which is commonly used in dentistry. X-ray radiation from panoramic radiography can cause biological damage, such as the increase of gingival crevicular fluid (GCF) volume. One of materials which was known having the ability to decrease the effect of panoramic radiography is β -carotene in mucoadhesive gingival patch form. The application of β -carotene mucoadhesive gingival patch reduce micronucleus increasing in previous study. The aim of this study is to determine the effect of β -carotene mucoadhesive gingival patch application on palatal gingiva of maxillary incisor teeth to the GCF volume of panoramic radiography exposed patients. This study involved 10 subjects (5 females and 5 males). The GCF sample was taken from the labial sulcus of 11, 12 teeth (treatment group) and 21, 22 teeth (control group) of each subject before and after panoramic radiography exposure. β -carotene mucoadhesive gingival patch was applied on palatal gingiva before panoramic radiography examination. Sample was collected using an absorbent paper which is inserted to the labial gingival sulcus. The GCF on the absorbent papers were marked by adding ninhydrin 2%, then the GCF volume was measured using a sliding caliper. Paired t-test result shows a significant difference between GCF volume in each group before and after panoramic radiography exposure ($p < 0.05$). Independent t-test shows no significant difference between the GCF volume difference in the control and treatment group ($p > 0.05$). The result of this study shows that the application of β -carotene mucoadhesive gingival patch on palatal gingiva of maxillary incisor teeth shows insignificant effect in decreasing the increase of GCF volume in panoramic radiography exposed patients.

Keywords: gingival crevicular fluid; panoramic radiography; β -carotene mucoadhesive gingival patch

INTRODUCTION

An X-ray radiographic examination is one of the supporting diagnosis procedures that cannot be separated from the field of dentistry.¹ Panoramic radiography is widely used in radiographic examinations in the field of dentistry. The panoramic radiography is a technique for taking tomography of facial structures which includes the teeth, maxilla, mandible, and other supporting structures using radiation exposure.² The principle of exposure to panoramic radiographs is that the patient is placed in a static position. The X-ray tube and cassette carrier move around the patient's head at the same speed.¹ The X-ray tube moves behind the patient's head, so the primary exposure to the anterior teeth comes from the back of the patient's head.^{1,2}

The effective dose in one exposure to panoramic radiographs is around 4.7-14.9 μ Sv.² The dose is lower than the dose for radiotherapy. However, a small dose of X-ray radiation is able to cause biological changes in living tissue. The interaction between X-rays and living tissue occurs through ionization and free radical formation reactions that can cause cell damage.³ Effective doses produced by panoramic radiographs have been shown to cause an increase in gingival sulcus fluid volume 10 minutes after exposure. The increasing of conventional radiography is greater than digital radiography.⁴

Gingival crevicular fluid (GCF) is a filtration product from a blood vessel that can be either transudate or exudate. Level of GCF volume in a

normal condition is very small, however GCF flow will increase in accordance with inflammation.⁵ Gingival crevicular fluid comes from the gingival microcirculation and has several components; blood material, protein, electrolytes, bacterial endotoxin, fibrinolysis system, desquamated epithelial cells, and urea.⁶ The GCF acts as a health marker of periodontal tissue and is known to play a role in the pathogenesis of periodontal disease or abnormalities.⁵

The interaction between X-ray radiation and living tissue can cause cell damage, so the use of ionizing radiation must be accompanied by radiation protection. One of the substances that can reduce the effects of radiation in normal tissue is β -carotene molecule. The β -carotene is known to have antioxidant and anti-inflammatory effects that can reduce the effects of radiation. The antioxidant mechanism of β -carotene against free radicals can occur through several pathways, namely free radical binding, electron transfer to free radicals, and hydrogen allylic.⁷ β -carotene can also act as an anti-inflammatory by suppressing the transcription and expression of proinflammatory cytokines.^{8,9}

β -Carotene has been previously tested to reduce the effects of panoramic radiation in the form of mucoadhesive gingival patches in rabbit and also in human.^{10,11} Applications of β -carotene on mucoadhesive gingival patches have been shown to reduce the increase in the number of micronuclei due to exposure to panoramic radiographs in rabbits.¹⁰ The assessment of micronucleus is a promising tool for the study of carcinogenesis biomarker. Micronucleus is a small nucleus that formed as chromosomal damage arisen from the lagging chromosomes at anaphase.¹¹ An increase in the number of micronuclei can also be prevented by using β -carotene patches after panoramic radiographs exposure, although statistically insignificant because of the limitation concentrate dose of β -carotene in the patch.¹² The β -carotene mucoadhesive gingival patch provided a good bioavailability of active substances in human mucosa because the form of a mucoadhesive patch allows increased absorption rates.¹² The aim of this study is to determine the effect of the β -carotene

mucoadhesive gingival patch application on the GCF volume of patients after panoramic radiography exposure.

MATERIALS AND METHODS

The study was quasi-experimental research and was in a non-equivalent control group design. In meeting the research ethics requirements, the study had obtained ethical approval in the form of issuing Ethical Clearance letters from the Ethics and Advocacy Unit of the Faculty of Dentistry, Universitas Gadjah Mada (No.00858/KKEP/FGK-UGM/EC/2016). The β -carotene patch was obtained from the previous study with the composition of hydroxypropylmethylcellulose (HPMC) E-15, CMC Na, β -carotene, propylene glycol, and aquades. The patch size was 5x15 mm or with a total patches area of 75 mm². The concentration of β -carotene in preparation stage calculated by a spectrophotometer was 0.485-0.555 μ g/10 mm² so that the concentration of β -carotene applied to each subject was 3.63-4.16 μ g.¹⁰

The 10 subjects in this study were patients who were exposed to panoramic radiographs aged 18-25 years, systemically healthy, healthy periodontal tissue conditions, no smoking, and no radiographs examination at least 2 weeks before the study. From each patient were taken panoramic radiographic examination divided into 2 groups; treatment and control groups. The treatment area was teeth elements 11 and 12 which received the application of β -carotene patches on the palatal gingival section before exposure to panoramic radiographs, while the control area were teeth elements 21 and 22 which did not receive a patch of β -Carotene. The samples GCF collected from the labial sulcus of each group before and after exposure to panoramic radiographs.

Gingival crevicular fluid samples from the treatment and the control group were collected 2 times, 30 minutes before exposure to panoramic radiographs and 10 minutes after exposure to panoramic radiographs. GCF sampling collection was done using filter paper inserted into the labial sulcus for 1 minute. Measurement of GCF sample volume was carried out by dropping 2% ninhydrin on filter paper. The absorption level of GCF was

obtained by measuring the height of the colour change on the filter paper at 3 reference points using the calliper unit in mm. Volume of GCF was obtained by multiplying the absorption height with the width and thickness of filter paper so that the volume was obtained in the unit of mm^3 . The volume obtained was then converted into μL unit ($1 \text{ mm}^3 = 1 \mu\text{L}$).

Panoramic radiographic exposure was performed with a panoramic radiographic machine (Yoshida Panoura, Japan) with specifications of 70-90 kVp, 10 mA, and exposure duration of 12 seconds, and a radiation distance of 37.6 cm at the Functional Medical Staff (FMS) of radiology in Prof. Sodom, UGM, Dental and Oral Hospital, Yogyakarta, Indonesia. The application of β -carotene patches on the palatal gingiva of the treatment group was carried out 5 minutes before exposure to panoramic radiographs using tweezers and mouth glass. The effect of the β -carotene patch application was seen based on increased GCF volume after exposure to panoramic radiographs. The Shapiro-Wilk test was employed to determine the data normality. If the data is normally distributed ($p > 0.05$), gingival crevicular fluid volume data before and after radiation exposure from each group would be tested using a paired t-test. Data comparison of GCF volume differences between groups was then tested using the independent t-test.

RESULTS

The results of GCF volume measurements before and after exposure are shown in Figure 1. There was an increase in GCF volume after exposure to panoramic radiographs in both the control group (0.078 ± 0.052) and in the treatment group (0.049 ± 0.046). The increase of GCF volume after exposure to panoramic radiographs in each group was statistically significant ($p < 0.05$). The results of the statistical analysis of the control group and treatment group are shown in Table 1. The increase of GCF volume in the treatment group was lower than the increase in GCF volume of the control group (Figure 1). However, the difference was not statistically significant ($p > 0.05$) (Table 1).

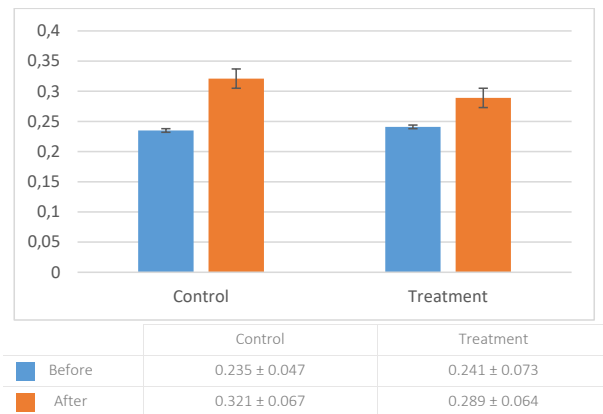


Figure 1. Graph of GCF volume before and after panoramic radiography exposure

Table 1. The statistical test results of the paired t-test and independent t-test

No	Data type	Paired t-test		Independent t-test	
		t value	Significance (p)	t value	Significance (p)
1.	Control group	-5.940	0.000*	-	-
2.	Treatment group	-3.337	0.009*	-	-
3.	Difference in GCF volume between control and treatment group	-	-	1.354	0.192

*Significant ($p < 0.05$)

DISCUSSION

The control group GCF volume experienced an increase from the average volume of $0.235 \pm 0.047 \mu\text{L}$ to $0.321 \pm 0.067 \mu\text{L}$ after exposure to panoramic radiographs. The increased GCF volume in the control group was statistically significant ($p < 0.05$). The results of the study are in accordance with

the previous studies⁴ on the effects of exposure to panoramic radiographs on GCF volume, i.e. there were significant differences in the GCF volume of the subject before and after exposure to panoramic radiographs. The increased GCF volume after exposure to panoramic radiographs may be caused by dilatation of blood vessels due

to exposure to radiation received by endothelial cells. Endothelial cells form blood vessel walls and are sensitive to radiation, thus small radiation doses can cause biological effects on endothelial cells.^{1,2} Gingival crevicular fluid in the treatment group also increased from the average volume of 0.241 μl to 0.289 μl . Volume of GCF before and after exposure to panoramic radiographs in the treatment group showed a statistically significant difference ($p < 0.05$). The significant increase in GCF volume after exposure to panoramic radiographs in the treatment group indicates that X-rays can still cause biological changes in cells even though β -Carotene in the form of mucoadhesive gingival patches has been applied to reduce the radiation effect. A mucoadhesive patch is a form of drug delivery system consisting of three membranes, namely bioadhesive polymer, membrane reservoir that releases controlled drugs, and non-permeable membranes that are dealing with oral mucosa.¹³ Mucoadhesive gingival patch dosage used in this study was clear, transparent physical properties, elastic, easily attached to the mucosa and was able to last for 4-6 hours.

The application of the β -Carotene patch was carried out on the tooth 11 of palatal gingiva and 12 subjects (treatment group) with the consideration that the source of X-ray radiation exposure of panoramic radiographs obtained from the anterior teeth was from the back of the patient's head. The exposure dose of panoramic radiographs was 4.7 μSv .¹⁴ The dose is higher than the dose received by the patient who is exposed to other dental radiographic techniques, such as periapical. The exposure dose has been shown to cause biological damage to normal tissue. The relationship between the radiation dose received and the biological effects produced is a relationship without a threshold. Thus even a small radiation dose can also cause biological damage.¹⁵

The average increase in GCF volume in the treatment group and the control group showed quantitative differences around $0.049 \pm 0.046 \mu\text{l}$ in the treatment group and $0.078 \pm 0.052 \mu\text{l}$ in the control group. Gingival crevicular fluid volume in the treatment group experienced a lower increase than

the control group. However, the difference was not statistically significant ($p > 0.05$) The results indicate that the application of the β -Carotene patch on the palatal gingiva of maxillary incisor teeth did not show a significant effect in preventing the radiation effect in the form of increasing GCF volume of patients exposed to panoramic radiographs. The condition is probably caused by the application of patches on the palatal gingiva while GCF volume uptake was done on the labial sulcus of the tooth. GCF production is associated with increased vascular permeability in the junctional epithelium and the gingival sulcular epithelium, and GCF flow originating from the gingival microcirculation and is influenced by the flow of capillary vessels leading to the gingiva.^{6,16,17} The difference of the blood flow sources in palatal gingiva and labial section can cause different GCF flow in each section. Palatal gingiva and labial sections are innervated and vascularized by different nerves and arteries. The labial section of the anterior tooth gingiva is innervated by the superior anterior alveolar nerve and is vascularized by the anterior superior alveolar artery. Palatal gingiva is innervated by the nasopalatine nerve and is vascularized by the nasopalatine artery.¹⁸

The action mechanism of the β -Carotene patch in reducing the radiation effects is through the β -Carotene antioxidant and anti-inflammatory action.⁷ The protective effect of the β -Carotene patch on panoramic radiation exposure occurs by breaking the reaction chains of oxidation and oxygen singlet. The system of drugs administration with the mucoadhesive method is the presence of bioadhesion that occurs between drug carrier material and mucosal surface. The bioadhesion of drug-carrying material with mucosal surfaces allows diffusion and increased bioavailability of the drug at the site of mucoadhesive patch application.¹²

The application of patches on the palatal gingiva is thought to only protect the palatal gingiva from radiation. In the other side, the labial gingiva was not protected from the patch application. The GCF retrieval was carried out in the labial gingival sulcus. GCF taken from the labial gingival sulcus can be a filtration product of the labial gingival

microcirculation. Labial gingiva gets exposure to X-ray radiation through the back of the patient's head.¹ The radiation exposure received by the gingiva in the labial section is probably smaller than the palatal section, because before reaching the gingiva the labial section of X-rays has passed various anatomical structures in the posterior part. The minimal X-ray exposure can still cause biological damage to the gingiva and cause an increase in GCF volume even though protection has been given in the form of a β -Carotene patch on the palatal gingiva. Another factor affecting the insignificant result of the application is the small dose of β -Carotene applied to the gingiva. It was only around 3.6375 - 4.1625 μg . The dose is hardly increased because it is related to the low solubility of β -Carotene to alcohol.¹¹ The low dose can also cause the disability of β -Carotene to resist oxidative stress received by the gingival endothelium due to exposure to panoramic radiographs. The oxidation reaction will still occur and continue to reach deeper cells if the antioxidant levels applied are not balanced with the oxidative stress received by cell.¹⁹ Thus the dosage of β -Carotene in the mucoadhesive gingival patch used is thought to be less effective in reducing the effects of radiation in the form of increasing GCF volume of patients exposed to panoramic radiographs. The dosage of β -Carotene received by the subject is likely to be enhanced by the application of a wider size of mucoadhesive gingival patches.

CONCLUSION

The application of the β -Carotene patch on the palatal gingiva of the maxillary incisor teeth did not have a significant effect in preventing the radiation effect in the form of increasing GCF volume of patients exposed to panoramic radiographs.

REFERENCES

- Whaites E, Drage N. Essentials of dental radiography and radiology, 5th Edition. China: Churchill Livingstone; 2013. 3. 65. 171-175.
- White SC, Pharoah MJ. Oral radiology principles and interpretation, 7th Edition. Canada: Mosby Elsevier; 2014. 17; 32-33: 166-167.
- Arora P, Devi P, Wazir SG. Evaluation of genotoxicity in patients subjected to panoramic radiography by micronucleus assay on epithelial cells of the oral mucosa. *J Dent (Tehran)*. 2014; 11(1): 47-55.
- Shantiningsih RR, Diba SF. Biological changes after dental panoramic exposure: conventional versus digital. *Dent J (Majalah Kedokteran Gigi)*. 2018; 51(1): 25-28. doi: 10.20473/j.djmk.v51.i1.p25-28
- Newman MG, Takei H, Klokkevold PR, Carranza FA. Carranza's Clinical Periodontology, 12th Edition. Canada: Elsevier Saunders; 2015. 216.
- Vindani D. Cairan sulkus gingiva dan peranannya dalam bidang kedokteran gigi. *Makara Kesehatan*. 2007; 1(2): 56-59.
- Mueller L, Boehm V. Antioxidant activity of β -carotene compounds in different in vitro assays. *Molecules*. 2011; 16: 1055-1069. doi: 10.3390/molecules16021055
- Bai SK, Lee SJ, Na HJ, Ha KS, Han JA, Lee H, Kwon YG, Chung CK, Kim YM. Beta-Carotene inhibits inflammatory gene expression in lipopolysaccharide-stimulated macrophages by suppressing redox-based nf-kappab activation. *Exp Mol Med*. 2005; 37(4): 323-334. doi: 10.1038/emm.2005.42
- Katsuura S, Imamura T, Bando N, Yamanishi R. Beta-Carotene and beta-cryptoxanthin but not lutein evoke redox and immune changes in RAW264 murine macrophages. *Mol Nutr Food Res*. 2009; 53(11): 1396-1405. doi: 10.1002/mnfr.200800566
- Shantiningsih RR. Patch gingiva mucoadesif β -carotene sebagai radioprotektor paparan radiografi panoramik (kajian in vivo pada kelinci Galur New Zealand). Fakultas Kedokteran Gigi, Universitas Gadjah Mada, Yogyakarta: Disertasi; 2014. 151-168.
- Jois HS, Kale AD, Kumar M. Micronucleus as potential biomarker of oral carcinogenesis. *IJDA*. 2010; 2(2): 197-202.

12. Shantiningsih RR, Diba SF. Efek aplikasi patch gingiva mukoadesif β -carotene akibat paparan radiografi panoramik. *Majalah Kedokteran Gigi Indonesia*. 2015; 1(2): 186-192. doi: 10.22146/majkedgiind.9121
13. Gilhotra RM, Ikram M, Srivastava S, Gilhotra N. A Clinical perspective on mucoadhesive buccal drug delivery systems. *J Biomed Res*. 2014; 28(2): 81-97. doi: 10.7555/JBR.27.20120136
14. Kurniawati L. Kalibrasi spasial citra radiografi dan kalibrasi dosis mesin sinar-x panoramik gigi. Fakultas Matematika dan Ilmu Pengetahuan Alam Universitas Gadjah Mada, Yogyakarta: Tesis; 2013; 12-14.
15. Lee KF, Weng JTYW, Hsu PWC, Chi YH, Chen CK, Liu IY, Chen YC, Wu LS. Gene expression profiling of biological pathway alterations by radiation exposure. *Biomed Res Int*. 2014; 1-8. doi: 10.1155/2014/834087
16. Wolf HF, Hassell TM. *Color atlas of dental hygiene-periodontology*. New York: Thieme Stuttgart; 2006. 10-12.
17. Reddy S. *Essentials of clinical periodontology and periodontics*. New Delhi: Jaypee Brothers Medical Publishers; 2008. 133-134.
18. Nelson SJ. *Wheeler's dental anatomy, Physiology, & Occlusion*, 10th Edition. China: Elsevier; 2015. 245 - 249.
19. Barrera G. Oxidative stress and lipid peroxidation products in cancer progression and therapy. *ISRN Oncology*. 2012; 2012: 1-22. doi: 10.5402/2012/137289