

## RESEARCH ARTICLE

# The effect of acellular dermal matrix therapy on biphasic calcium sulfate bone graft

Angga Febriharta\*, Kwartarini Murdiastuti\*\*✉

\*Periodontics Specialty Program, Faculty of Dentistry, Universitas Gadjah Mada, Yogyakarta, Indonesia

\*\*Department of Periodontics, Faculty of Dentistry, Universitas Gadjah Mada Yogyakarta, Indonesia

\*\*JI Denta No 1, Sekip Utara, Yogyakarta, Indonesia; ✉ correspondence: [kmurdiastuti@ugm.ac.id](mailto:kmurdiastuti@ugm.ac.id)

Submitted: 24<sup>th</sup> July 2018; Revised: 24<sup>th</sup> February 2019; Accepted: 20<sup>th</sup> November 2019

---

### ABSTRACT

Infrabony pocket therapy is needed to eliminate pocket wall, creating easy to clean conditions for new attachment, and bone regeneration. Biphasic calcium sulfate (BCS) bone grafts combined with collagen membranes are known to regenerate bone tissue and have good osteoconductive effects. The addition of collagen membranes promotes migration and proliferation of fibroblast cells, osteoblasts, and homeostasis. However, the collagen membrane is a rapid biosynthesis and may cause disease transmission from animal. Acellular dermal matrix (ADMA) membrane contains a bioactive matrix that has the ability to support normal revascularization, cell repopulation, and tissue remodeling. Combination of BCS with ADMA membrane are proven to induce bone and tissue regeneration. The objective of this study is to determine the therapeutic effect of BCS and ADMA combination to eradicate pocket, gingival recession, bone recession and attachment loss. The samples were taken from 20 infrabony pocket sites divided into 2 groups. The first was treated by combination of BCS and ADMA, while the second group was treated by the combination of BCS and collagen membrane. After 1 and 3 months of flap surgery, the result was observed by probing depth (PD), relative attachment loss (RAL), gingival recession, alveolar bone height and radiological examination. The result showed the decrease of PD, RAL, gingival recession, and alveolar bone height in both two groups. However, there were no significant differences between those two groups. In conclusion, the combination of BCS and ADMA or BCS and collagen decreased the PD, RAL, gingival recession and alveolar bone height.

**Keywords:** ADMA membrane; BCS; collagen membrane; infrabony pocket

---

### INTRODUCTION

Periodontitis was an inflammatory reaction caused by bacteria and manifested in irreversible periodontal tissue destruction.<sup>1</sup> The disease progresses pathologically and progressively from periodontal ligaments and alveolar bone with the formation of periodontal pockets, recessions, or both.<sup>2</sup> Bone graft treatment using bone graft materials could induce bone formation and regenerate new attachment of periodontal processes.<sup>3</sup> To determine the success of the periodontal pocket, there were several clinical parameters to determine its success, between the parameters of probing depth, attachment loss, and alveolar bone height.<sup>4</sup>

Biphasic calcium sulfate (BCS) was one of the bone graft materials that has its microporous

properties, allowing stronger osteoblast infiltration to remain embedded and crystallize, thereby enabling the formation of excellent scaffolds that will enhance the osteoblast differentiation activity. In this way, the superiority of BCS makes it a potential material for bone graft.<sup>5,6</sup> Reported increases in gingival recession due to shrinkage in bone grafts were mainly due to inflammatory tissue healing. This fact is in line with the reported findings of an increase in gingival recession by 1.28 mm and 1.20 mm after 6 months of graft material installation.<sup>7,8</sup> The use of collagen membranes in infrared pocket therapy with or without the addition of bone graft can improve the regeneration of periodontal tissue.<sup>9</sup> However, the drawback of this membrane is the loss of space keeping ability in humid conditions, easy

resorption, and the risk of disease transmission to humans.<sup>10</sup>

Acellular dermal matrix (ADMA) could be used as a membrane obtained from human skin. This process was done by removing the dermal cell portion and leaving the bioactive matrix portion that the body needs for regeneration and healing.<sup>11</sup> Clinical studies using ADMA as a membrane for guided bone regeneration in toothless areas in the installation of immediate implants indicate that this material may serve as membranes.<sup>12</sup> The objective of this study is to determine the effect therapy of BSC and ADMA combination to eradicate pocket, gingival recession, bone recession, and attachment loss.

## MATERIALS AND METHODS

The methods of this study was approved by the Ethics Committee of the Faculty of Dentistry, Universitas Gadjah Mada (Ethical Clearance No. 001417 / KKEP / FKG-UGM / EC / 2018). A signed informed consent was got from each participant in this study. The samples were taken from 20 infrabony pocket sites of chronic periodontitis patients divided into 2 groups. The first group was treated by combination of BCS and ADMA, while the second group was treated by the combination of BCS and collagen membrane.

The preparatory stage in the patient was done by subject selection according to inclusion and exclusion criteria, informed consent signing, and scaling and root planing of the patient. The stage of the study consisted of measurements of PD, RAL, high gingival recessions, and alveolar bone height using periodontal probes at the distobuccal, buccal, mesiobuccal, mesiolingual, lingual, and distolingual site on the second visit (a week after the first visit). The measurement of PD was performed on the gingival margin to the bottom of the pocket. The measurement of RAL was performed on the determined CEJ point to the bottom of the pocket. The height measurement of gingival recession was done on the gingival margin to the cemento enamel junction from the vertical direction, and the measurement of the height of the alveolar bone was performed on the CEJ and the most apical base of

the defect from the vertical direction of the X-ray of CBCT.

The surgery was performed on the patient by firstly taking asepsis in the surgical area. Infiltration of anesthesia was carried out on the area of operation and continued with full vertical and sulcular incidents of full-thickness flap. The flap was observed and debridement was conducted on the defect area with scaling root planning and curettage. Tetracyclin HCL of 75 mg / ml was applied on the root surface with sterile pellet cotton for 3 minutes, which was replaced every 30 seconds, and rinsed with aquadest. Furthermore, BCS material was applied to bone defects and it was closed with ADMA membrane in group I and collagen membrane in group II, which have been prepared before. The flap was positioned towards the coronal until it closed the collagen membrane. Afterwards, it was stitched and covered with a periodontal dressing.

The post-surgery patient was informed and instructed about how to care for postoperative tooth and mouth. He was required to have a control 7 days later to release periodontal dressing. On the 30<sup>th</sup> day and 90<sup>th</sup> day, PD, CALs, high gingival recessions, and alveolar bone height were measured.

## RESULTS

In this study, the data were collected from clinical parameters and radiological examination measurements in two groups of chronic periodontitis patients with infrabony defect. Regenerative treatment was done using open flap method with addition of BCS. Membrane of ADMA was applied in group I, while treatment using open flap method was done with the addition of BCS, and collagen membrane was done in group II. Data obtained in this research were PD, RAL, high gingival recession, alveolar bone damage, and radiological examination.

Table 1 and Figure 1 show the highest mean of PD in the BCS + ADMA membrane group on day 0 (baseline),  $7.30 \pm 1.64$  mm. The lowest mean of PD was in BCS + collagen membrane on day 90. The initial value of PD measurement differed between the two treatment groups, so it was necessary to see the magnitude of the reduction difference of PD

in each group for further significance test. The data in Table 2 indicates that the average reduction of PD was highest in the BCS + collagen from day 0 to day 90, and the lowest reduction value in the BCS + collagen membrane group was on day 30 to day 90. The mean value of PD reduction was greater in the BCS + membrane group of ADMA in all groups and it was greater than the mean reduction value in the BCS + collagen membrane group. Mann-Whitney U test of PD reduction in all groups showed a significance value of  $p > 0.05$ , and thus indicating no significant difference between groups at the same time (Table 3).

Tables 4 and 5 demonstrate a significant difference of PD reduction at each observation time for the same group, except on the day 0 to day 30 and day 0 to day 90 on BCS + collagen membrane group. Table 6 and Figure 2 depict the highest average RAL in the BCS + ADMA membrane group on day 0 (baseline). The average RAL was at the lowest in the BCS + collagen membrane group on day 90. It was important to note the difference of RAL reduction in each group because the initial value of RAL measurement was different for further significance test.

The data in Table 7 shows that the average RAL reduction was at the highest in the BCS + collagen membrane group on day 0 to day 90, and the reduction value of PD was at the lowest in the BCS + collagen membrane group on day 30 to day 90. The mean value of RAL reduction was greater in the BCS + collagen membrane group than in the BCS + membrane ADMA group. Except on day 30 to 90, the mean RAL value of the BCS + group of ADMA membrane was comparable to that in the BCS + collagen membrane group.

Table 8 illustrates the results of the Mann-Whitney U test reduction RAL test with a significance value of  $p > 0.05$ , so that there was no statistically significant difference between groups on day 0 to day 30, day 30 to day 90, and day 0 to day 90. Tables 9 and 10 delineate a significant difference of RAL reduction at each observation time for the same group.

Table 11 and Figure 3 highlight the highest mean gingival recession in the BCS + ADMA

membrane group on day 30. The highest rate of gingival recession was at the lowest in the BCS + collagen membrane group on day 90.

The data in Table 12 indicates that the mean reduction of gingival recession height was at the highest on day 30 of BCS + ADMA membrane group to day 90, and the reduction value of gingival recession height was at the lowest in the BCS + ADMA membrane group on day 0 to day 30. The mean rate of gingival recession height reduction was greater in the BCS + collagen membrane group in all groups except on day 30 to 90 compared to the mean reduction value in the BCS + ADMA membrane group.

Mann-Whitney U test results for the reduction of gingival recession height in all groups showed a significance value of  $> 0.05$ , which means that there was no statistically significant difference between groups in the measurement of day 0 to day 30, day 30 to day 90, and day 0 to day 90 (Table 13). Table 14 and 15 present no significant difference in the high reduction of gingival recession at each observation time in all groups of both BCS + membrane groups ADMA and BCS + collagen membranes.

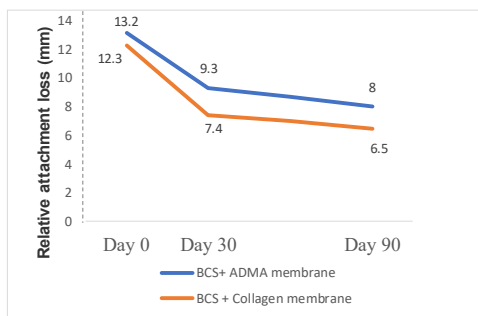
Table 16 shows the highest mean alveolar bone in the BCS + ADMA membrane group on day 0 (baseline). The average height of the alveolar bone was at the smallest in the BCS + collagen membrane group on day 90. The significance level of the paired t-test parametric obtained p value  $< 0.05$ , which means that there were significant differences in alveolar bone height improvement between observation times in each group (Table 17).

Initial values of alveolar bone height measurement differed between the two treatment groups, so it was necessary to see the magnitude of the high-alveolar bone reduction difference in each group for subsequent significance tests. The data in the Table 18 shows that the high alveolar bone reduction rate in the BCS + collagen membrane group was higher than the BCS + ADMA membrane group. The result of the independent t-test on the high alveolar bone reduction showed a significance value of  $p > 0.05$ , meaning that there was no statistically significant difference between the

BCS + ADMA membrane group and the BCS + collagen membrane group (Table 19).

**Table 1.** The mean and standard proportion of probing depth (PD) deposits by observation time and treatment group (mm)

Time	n	BCS+ ADMA membrane	BCS+ collagen membrane
Baseline	10	7.30 ± 1.64	6.30 ± 0.67
Day 30	10	2.90 ± 0.99	2.30 ± 0.67
Day 90	10	2.10 ± 0.74	1.80 ± 0.63



**Figure 1.** Average diagram of probing depth (mm)

**Table 2.** Mean and standard probing depth reduction (PD) by observation time and treatment group (mm)

Time	n	BCS + ADMA membrane	BCS+ Collagen membrane
Day 0 to day 30	10	4.40 ± 1.65	4.00 ± 0.82
Day 30 to day 90	10	0.80 ± 1.03	0.50 ± 0.71
Day 0 to day 90	10	5.20 ± 1.32	4.50 ± 0.85

**Table 3.** Mann-Whitney U test of probing depth (PD) reduction between the treatment group

Time	Signification	Notes
Day 0 to day 30	0.529	Not significant
Day 30 to day 90	0.796	Not significant
Day 0 to day 90	0.218	Not significantt

**Table 4.** Wilcoxon test result on pocket depth reduction (PD) by observation time in group BCS + ADMA membrane (mm)

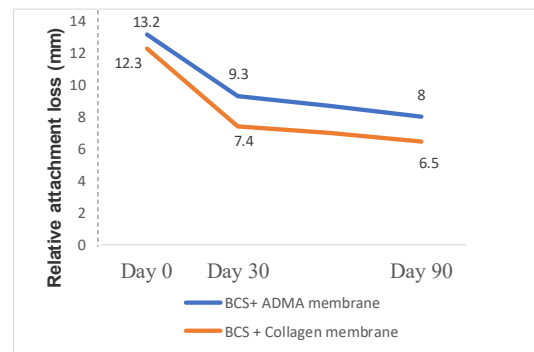
PD reduction	BCS + ADMA membrane		
	0-30	30-90	0-90
BCS + ADMA membrane	0-30	0.08*	0.039*
	30-90		0.005*

**Table 5.** Wilcoxon test result on pocket depth (PD) reduction by observation time in BCS + Collagen membrane Group (mm)

Pocket depth (PD reduction)	BCS + Collagen membrane		
	0-30	30-90	0-90
BCS + Collagen membrane	0-30	0.005*	0.059
	30-90		0.005*

**Table 6.** Mean relative attachment loss (RAL) and standard deviation by observation time and treatment group (mm)

Time	n	BCS + ADMA membrane	BCS + collagen membrane
Day 0	10	13.20 ± 1.69	12.30 ± 1.64
Day 30	10	9.30 ± 1.83	7.40 ± 1.78
Day 90	10	8.00 ± 2.16	6.50 ± 1.58



**Figure 2.** Average diagram of relative attachment loss (mm)

**Table 7.** Mean and standard raw reduction of relative attachment loss (RAL) according to observation time and treatment group (mm)

Time	n	BCS + ADMA membrane	BCS + collagen membrane
Day 0 to day 30	10	3.90 ± 0.99	4.90 ± 1.45
Day 30 to day 90	10	1.3 ± 0.95	0.90 ± 0.99
Day 0 to day 90	10	5.20 ± 1.48	5.80 ± 1.140

**Table 8.** Result of Mann-Whitney U test against reduction relative attachment level (RAL) among treatment groups

Time	Level of significance	Notes
Day 0 to day 30	0.105	Not Significant
Day 30 to day 90	0.436	Not Significant
Day 0 to day 90	0.353	Not Significant

**Table 9.** Wilcoxon test results on relative attachment level (RAL) reduction by observation time in BCS + ADMA membrane group

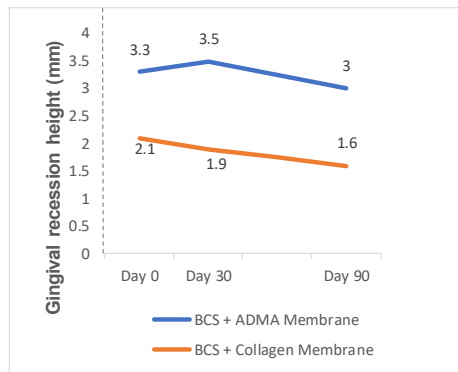
RAL reduction	BCS + ADMA membrane		
	0-30	30-90	0-90
BCS + ADMA membrane	0-30	0.007*	0.010*
	30-90		0.005*

**Table 10.** Wilcoxon test result on relative attachment level (RAL) reduction by observation time in BCS + collagen membrane group

RAL reduction	BCS + collagen membrane		
	0-30	30-90	0-90
BCS + collagen membrane	0-30	0.005*	0.034*
	30-90		0.004*

**Table 11.** Average and standard deviation of gingival recession height by observation time and treatment group (mm)

Time	n	BCS + ADMA membrane	BCS + Collagen membrane
Day 0	10	3.30 ± 2.54	2.10 ± 0.74
Day 30	10	3.50 ± 2.46	1.90 ± 0.57
Day 90	10	3.00 ± 2.36	1.60 ± 0.52



**Figure 3.** Average diagram of gingival recession height (mm)

**Table 12.** The mean and standard deviation of gingival recession height reduction by observation time and treatment group (mm)

Time	n	BCS + ADMA membrane	BCS + collagen membrane
Day 0 to day 30	10	-0.20 ± 1.03	0.20 ± 0.79
Day 30 to day 90	10	0.50 ± 0.97	0.30 ± 0.67
Day 0 to day 90	10	0.30 ± 1.06	0.50 ± 0.71

**Table 13.** Mann-Whitney U test results against gingival recession height reduction between treatment groups

Observation time	Level of significance	Notes
Day 0 to day 30	0.353	Not significant
Day 30 to day 90	0.796	Not significant
Day 0 to day 90	0.481	Not significant

**Table 14.** Wilcoxon test result on gingival recession height reduction by observation time in BCS + ADMA membrane group

Reduction of gingival recession height	BCS + ADMA membrane		
	0-30	30-90	0-90
BCS + ADMA membrane	0-30	0.230	0.129
	30-90		0.1577

**Table 15.** Wilcoxon test result on reduction of gingival recession height by observation time in BCS + collagen membrane group

Reduction of gingival recession height	BCS + collagen membrane		
	0-30	30-90	0-90
BCS + collagen membrane	0-30	0.527	0.180
	30-90		0.414

**Table 16.** Average and standard deviation of alveolar bone height by observation time and treatment group (mm)

Time	n	BCS + ADMA membrane	BCS + collagen membrane
Day 0	10	9.76 ± 4.54	8.17 ± 2.60
Day 90	10	8.81 ± 4.39	6.94 ± 2.68

**Table 17.** Parametric paired t-test results on alveolar bone height in each treatment group

Group	Level of significance (p)	Notes
BCS + ADMA membrane	0.000	Significant
BCS + collagen membrane	0.002	Significant

**Table 18.** Average and standard deviation of alveolar bone height reduction by observation time and treatment group (mm)

Time	n	BCS + ADMA membrane	BCS + collagen membrane
Day 0 to day 90	10	0.95 ± 0.50	1.23 ± 0.87

**Table 19.** T-test results of alveolar bone height reduction among treatment groups

Observation time	Level of significant	Notes
Day 0 to day 90	0.396	Not significant

## DISCUSSION

Statistical test results on probing depth decrease, relative attachment loss, and high gingival recession between BCS + ADMA membrane group and BCS + collagen membrane group showed insignificant results. The ADMA membrane has a bioactive matrix consisting of collagen, elastin, and blood vessel channels. In addition, bioactive proteins have the ability to support natural revascularization, cell repopulation and tissue remodeling leading to good tissue regeneration. The existence of this matrix structure can decrease the induced response of excessive inflammation.<sup>13</sup> On the other hand, the ADMA membrane has a tendency to have an extended healing process due to delayed blood vessel formation of the ADMA membrane. ADMA membranes can not perform anastomose with the underlying tissue, so it takes time for angiogenesis to occur.<sup>14</sup>

Collagen membranes can induce more proliferation of fibroblasts and osteoblasts. In addition, the collagen membrane has semipermeable properties allowing nutrient penetration and the

presence of cell attachment on the membrane surface stimulates tissue regeneration.<sup>15</sup> There were deficiencies in collagen membrane, such as faster absorption. Such deficiency caused poor wound healing process because the collagen membrane had been absorbed by the body on the 14th day, while the phase of peak proliferation occurred at week 2 to week 3.<sup>16</sup> The healing process of surgery began immediately after suturing, and lasted over time from the phases of hemostasis, inflammation, proliferation, and remodeling.<sup>3</sup> In the hemostasis phase, the space between the flap and the surface of the bone was filled by a blood clot consisting of fibrins with large polymorphonuclear leukocytes, erythrocytes and debris from damaged cells with capillaries at the wound end. After the hemostasis phase, the healing process continued with an inflammatory phase that peaked from day 2 to day 3. Then, it proceeded with a proliferation phase that peaked at week 2 to week 3, while the remodeling phase began at the peak of the proliferation phase at week 3 or day 21, where optimal results of intrabony damage repair can be seen from the reduction of probing depth.<sup>16</sup>

The data of a high alveolar bone value of day 30 is lower than day 0. Higher alveolar bone values indicate bone repair where a decrease in alveolar bone height indicates a periodontal tissue regeneration that appears to be a radiopaque area in the x-ray image.<sup>17</sup> This is consistent with studies using biphasic calcium sulfate as a socket therapy after retraction with visible results of vital bone formation.<sup>18</sup>

Healing of bone fracture occurred after one month of bone grafting and after 3 months as evident on radiographic examination. The process of mineralization and bone density will increase significantly six months after bone graft planting.<sup>19</sup>

The mean reduction of alveolar bone damage between day 0 to day 90 of BCS + collagen membrane group was greater than that of BCS + ADMA membrane group. The reduction results in the BCS + group of larger collagen membranes may be attributed to the collagen membrane which had the potential to induce osteoblasts, thereby resulting in bone regeneration.<sup>9</sup>

High alveolar bone reduction test resulting in differences in alveolar bone damage between BCS + collagen membrane group and BCS + ADMA membrane group was not significant. This showed the same alveolar bone regeneration between the two groups. Both groups were equally using BCS as bone graft. The presence of BCS will provide scaffold in bone formation. In addition, BCS can increase osteoblast differentiation activity to improve bone regeneration.<sup>5</sup> The maturation of bone graft in the laminar bone requires varying healing time, ranging from 3 to 6 months depending on some factors, such as age, wound healing factor, and bone damage measurement in bone grafted areas.<sup>20</sup>

## CONCLUSION

Research on the difference of therapeutic results between the addition of acellular dermal matrix membrane and collagen membrane on biphasic calcium sulfate bone graft showed no differences in the increase of probing depth, relative attachment loss, high gingival recession, and alveolar bone height in either acellular dermal matrix collagen membrane.

## REFERENCES

1. Preshaw PM, Alba AL, Herrera D, Jepsen S, Konstantinidis A, Makrilakis K, Taylor R. Periodontitis and diabetes: a two-way relationship. 2012; 55(1): 21-31. doi: 10.1007/s00125-011-2342-y
2. Kaushal S, Kumar A, Khan MA, Lal N. Comparative study of nonabsorbable and absorbable barrier membranes in periodontal osseous defects by guided tissue regeneration. *J Oral Bio Craniofac Res.* 2016; 6(2): 111-117. doi: 10.1016/j.jobcr.2015.12.001
3. Newman MG, Takei HH, Carranza FA, Klokkevold PR. Carranza's clinical periodontology 11<sup>th</sup> ed. Philadelphia: W.B.Saunders Co; 2012. 50-51, 550-555, 587.
4. Reynolds MA, Kao RT, Nares S, Camargo PM, Caton JG, Clem DS, Fiorellini JP, Geisinger ML, Mills MP, Nevins ML, Rosen PS. Periodontal regeneration – intrabony defects: practical applications from the AAP

- regeneration workshop. *Clinical Advances in Periodontics*. 2015; 5(1): 21-29.  
doi: 10.1902/cap.2015.140062
5. Pietrzak WS, Ronk R. Calcium sulfate bone void filler: a review and a look ahead. *J Craniofac Surg*. 2000; 11(4): 327-334.  
doi: 10.1097/00001665-200011040-00009
  6. Baranes D, Kurtzman GM. Biphasic calcium sulfate as an alternative grafting material in various dental applications. *J Oral Implantol*. 2019; 45(3): 247-255.  
doi: 10.1563/aaid-joi-D-18-00306
  7. Sculean A, Pietruska M, Schwarz F, Willershausen B, Arweiler NB, Auschill TM. Healing of human intrabony defects following regenerative periodontal therapy with an enamel matrix protein derivative alone or combined with a bioactive glass. A controlled clinical study. *J Clin Periodontol*. 2005; 32(1): 111-117.  
doi: 10.1111/j.1600-051X.2004.00635.x
  8. Mengel R, Schreiber D, Jacoby LF. Bioabsorbable membrane and bioactive glass in the treatment of intrabony defects in patients with generalized aggressive periodontitis: results of a 5 years clinical and radiological study. *J Periodontol*. 2006; 77(10): 1781-1787.  
doi: 10.1902/jop.2006.060029
  9. Chung Y, Lee J, Jeong S. Comparative study of two collagen membranes for guided tissue regeneration therapy in periodontal intrabony defects: a randomized clinical trial. *J Periodontal Implant Sci*. 2014; 44(4): 194-200.  
doi: 10.5051/jpis.2014.44.4.194
  10. Wang J, Wang L, Zhou Z, Lai H, Xu P, Liao L, Wei J. Biodegradable polymer membranes applied in guided bone/tissue regeneration: a review. *Polymers (Basel)*. 2016; 8(4): 115.  
doi: 10.3390/polym8040115
  11. Jayavel K, Swaminathan M, Kumar S. Ridge augmentation and root coverage using acellular dermal matrix: a case report. *Dent Res J*. 2010; 7(2): 88-91.
  12. Esfahanian V, Farhad S, Sadighi Shamami M. Comparison of ADM and connective tissue graft as the membrane in class II furcation defect regeneration: randomized clinical trial. *J Dent Res Dent Clin Dent Prospects*. 2014; 8(2): 101-106.  
doi: 10.5681/joddd.2014.018
  13. Taib H, Abidin KZ, Ali TBT, Yunus N. Socket preservation using acellular dermal matrix allograft in combination with xenograft for dental implant placement in anterior maxilla: a case report. *Sains Malaysiana*. 2014; 43(5): 745-750.
  14. Reza KM, Babak I, Niloofar N. Comparison of the effect of exposed (semi-covered) technique of ADMA (Acellular Dermal Matrix Allograft) in increasing the width of attached gingiva. *J Appl Environ Biol Sci*. 2015; 5(12): 253-261.
  15. Susanto A, Susana S, Pontjo B, Satari MH. Membran guided tissue regeneration untuk regenerasi periodontal. *J Dentika Dent*. 2015; 18(2): 300-304.
  16. Larjava H. Oral wound healing. Canada: John Wiley and Sons; 2012.
  17. Eickholz P, Krigar DM, Kim TS, Reitmer P, Rawlinson A. Stability of clinical and radiographic results after guided tissue regeneration in infrabony defects. *J Periodontol*. 2007; 78(1): 37-46.  
doi: 10.1902/jop.2007.060097
  18. Horowitz RA, Rohres MD, Prasad HS, Tovar N, Mazor Z. Enhancing extraction socket therapy with a biphasic calcium sulfate. *Compend Contin Educ Dent*. 2012; 33(6): 420-428.
  19. Groeneveld EH, Burger EH. Bone morphogenetic proteins in human bone regeneration. *Eur J Endocrinol*, 2000; 142(1): 9-21.  
doi: 10.1530/eje.0.1420009
  20. Hallman M, Ludgren S, Seneby L. Histologic analysis of clinical biopsies taken 6 months and 3 years after maxillary sinus floor augmentation with 80% bovine hydroxyapatite and 20% autogenous bone mixed with fibrin glue. *Clint Implant Dent Relat. Res*. 2001; 3(2): 87-96.  
doi: 10.1111/j.1708-8208.2001.tb00236.x