

# Head Lice Eradication Efforts in a Group Home Environment: Yayasan Griya Asih Orphanage – A Case Study

Natalia Puspadewi<sup>1\*</sup>, Christian Ardianto<sup>2</sup>, Gisella Anastasia<sup>1</sup>

<sup>1</sup>Medical Education Unit, School of Medicine and Health Sciences, Universitas Katolik Indonesia Atma Jaya, Jakarta, Indonesia

<sup>2</sup>Department of Histology, School of Medicine and Health Sciences, Universitas Katolik Indonesia Atma Jaya, Jakarta, Indonesia

Submitted: February 20<sup>th</sup> 2023; Revised: March 27<sup>th</sup> 2023; Accepted: March 31<sup>st</sup> 2023

## Keywords:

Education  
Head lice infestation  
Orphanage  
Pediculocides  
Transmission chain

**Abstract** Children living in orphanages are generally vulnerable to close-contact transmission diseases, including head lice infestation. The clinical manifestation of head lice infestation was relatively mild, such as itchy scalp, and hence it is often overlooked as a community health issue. Education plays an essential role in preventing re-infection and eradicating head lice infestation. The treatment options include chemical treatment using pediculicides and physical management by shaving the head and manually removing the parasite. This community service activity aimed to eradicate head lice from Yayasan Griya Asih Orphanage. A series of three activities were conducted at Yayasan Griya Asih Orphanage in Central Jakarta. Each activity was done around one month apart to evaluate the effectiveness of treatment. First-year medical students were recruited to participate in these activities to familiarize them with real-world community health problems. Student volunteers helped applied pulse doses of Permethrin 1% shampoo and provided health education activity. Fifty-five Yayasan Griya Asih Orphanage residents joined this activity from mid-October until December 2022. Residents were instructed not to share their personal items to prevent re-infection. Health education activities were done using one-to-many followed by a one-on-one format. In conclusion, head lice infestation screening is essential in crowded environments, and permethrin 1% pulsed dose followed by personalized health education activities and pest control effectively broke the disease transmission chain and eradicated the head lice infestation.

## 1. INTRODUCTION

Children living in a group home environment, such as an orphanage, are generally vulnerable to diseases associated with close-contact transmission and hygiene level (Benca, 2012). Parasitic infection, particularly head lice infestation, is one form of parasitic infection commonly found yet frequently neglected in school-aged children living in an orphanage, especially those with low hygiene levels (Bartosik, K. et al., 2022; Kim et al., 2015; Restapaty et al., 2019). Head lice or *Pediculosis capitis* is primarily transmitted through direct contact, where the adult parasite leapt from one head to another, or through indirect contacts, such as shared use of a hair comb or brush (Bartosik, K. et al., 2022). Several studies reported different head lice

prevalence in school-aged children in Indonesia. A study conducted in North Sulawesi reported that the prevalence of head lice infestation among children aged 7-12 y.o. was 18.7% (Rumampuk, 2014). On the other hand, the prevalence of head lice infestation was 55.4% among high school students living in dorms in Bogor, 34.9% among school-aged children living in one Pondok Pesantren in Medan (Massie et al., 2020), 40,7% among orphans in one orphanage in Riau (Maryanti & Lestari, 2020), and 57,5% among orphans in one orphanage in Pekanbaru (Maryanti et al., 2018).

The different prevalence numbers reported in each study suggested that although crowded living arrangements and

personal hygiene level might contribute to aggravating head lice infestations in group home environment, existing contact history with an infected person may be a more significant risk factor for this disease (Massie et al., 2020; Rumampuk, 2014; Suweta, 2021). Risk factors influencing head lice infestation include gender, age, and bed arrangements. Females aged 5-13 y.o. have a higher risk of head lice infection compared to males and older age groups (Lye et al., 2017; Maryanti & Lestari, 2020; Maryanti et al., 2018; Nutanson et al., 2008); People who share a bedroom also have a higher risk to get head lice infestation (Gharsan et al., 2016).

Head lice or *Pediculus humanus capitis* can only live in their host's body (Massie et al., 2020). Once infected, the host will mainly experience itchiness on their scalp due to hypersensitivity reactions to the parasite's saliva and feces. In some cases, the host may report excoriation and conjunctivitis (Massie et al., 2020; Suweta, 2021). The clinical manifestation of head lice infestation was relatively mild; hence it is often overlooked as a community health issue (Bartosik, K. et al., 2022; Suweta, 2021). Fortunately, head lice infestation treatment is relatively easy and widely available.

The treatment options include chemical treatment using *pediculicides*, such as Permethrin and Lindane, and physical management by shaving the head and manually removing the parasite (Hardiyanti et al., 2015). Physical management also aids with applying chemical treatment and prevents re-infection (Hardiyanti et al., 2015). Education is an essential component to eradicate head lice infestation in a group home because although the treatment is easily accessible, the potential re-infection rate is relatively high if the parasites, both in their adult and egg forms, are not entirely eradicated from the dwelling (Hardiyanti et al., 2015).

Yayasan Griya Asih Orphanage is an orphanage located in Central Jakarta. It provides shelter to street children and children from families who cannot afford to provide appropriate care for them (Panti Asuhan Griya Asih, 2020). In October 2022, the orphanage sheltered 55 people, consisting of 18 elementary school-aged children (up to 12 y.o., 13 males and 5 females) and 37 teenagers and young adults (13 y.o. or above, 30 males and 7 females).

During one of the visits to this orphanage, all female children showed indications that they had lice on their heads. When asked, several children were able to point out that the girls suffered from head lice infection and were quite adept in removing the lice from the girls' hair by hand, suggesting that this was not the first time this incident occurred in this place. Universitas Katolik Indonesia Atma Jaya, School of Medicine and Health Sciences had been conducting several community service activities at this site; hence, a relationship with the orphanage residence was already established.

Yayasan Griya Asih Orphanage has six rooms in the dorm area. However, there were only six beds in one room, and each room in the dorm area held around eight to ten children. Typically, one bedroom was shared by older and

younger children and teenagers. Each room had one older teenager who functioned as the 'room supervisor' in charge of keeping the room clean. Due to limited space, there were instances where two or more children shared a bed in the same bedroom.

The communal living arrangement and item-sharing behaviour in this place aroused a suspicion that there might be others aside from those children who also suffered from *Pediculosis capitis* yet went unnoticed, potentially creating an infectious chain that might cause unnecessary prolonged head lice infestation in this dwelling. Although there were only several children claiming to suffer from head lice infestation, this situation might worsen if not treated promptly because they shared six beds in one bedroom (see Figure 1). Further, their tendency to share towels and hair combs could also aggravate this situation.

This situation prompted us to organize community service activities to eradicate head lice from Yayasan Griya Asih Orphanage to improve the health and well-being of all residents. The ultimate goal of these community service activities was to eradicate head lice infestation at Yayasan Griya Asih Orphanage.



Figure 1 . Bed arrangements in Yayasan Griya Asih Orphanage: (a) Initial condition; (b) Current condition

## 2. METHOD

Since *Pediculosis capitis* is a highly transmissible disease requiring at least two to three weeks of treatment to eradicate the parasites, health promotion through educational activities was conducted in addition to providing appropriate medical treatment to eradicate the head lice infestation in this site. The educational activities aimed to induce behavioural changes in Yayasan Griya Asih Orphanage, particularly in improving the residents' personal and communal hygiene behavior and improving

their knowledge of head lice infestation and simple ways they could do to prevent future re-infections.

Being aware of the orphanage's limitation to eradicate head lice infestation by themselves, direct therapeutic and other measures, including providing individual towels and combs as well as new beddings, were also organized to solve this issue. The team also provided information and obtained informed consent regarding the planned activities toward Yayasan Griya Asih Orphanage's administrator and caretakers, who also acted as the legal guardian for all Griya Asih residents. Permission was obtained from the orphanage's administrator prior to conducting any community service activities on this site.

Funds needed to conduct these community service activities were raised through social media. Pictures of Yayasan Griya Asih Orphanage's living situations, a short explanation of their health issues, and what was needed regarding funds and items required to solve their problems were posted on the team members' social media. The choice of direct item donations (including Permethrin 1% shampoo, hair towels, nit combs, and new beddings) and monetary donations were provided. All community service activities at Yayasan Griya Asih Orphanage were funded through this donation.

A series of three community service activities were conducted at Yayasan Griya Asih Orphanage in Central Jakarta. These activities were held on October 16, November 19, and December 17, 2022. Each community service activity was done around one month apart because the effectiveness of the Permethrin 1% treatment could only be evaluated after the third week.

First-year medical students were recruited to participate in this community service to familiarize them with real-world community health problems and improve empathy. Ten, four, and two first-year medical students were involved in the first, second, and third community service activities, respectively.

All Yayasan Griya Asih Orphanage residents were considered to have *Pediculus capitis* before the first Permethrin 1% shampoo treatment. Student volunteers helped apply Permethrin 1% shampoo, followed by providing health education activity, including personal hygiene and knowledge about head lice to improve the treatment's success rate and prevent further infestation. Instructions and a two-minute video of proper combing techniques to remove the hair parasites were left to Yayasan Griya Asih Orphanage's caretaker to repeat the Permethrin 1% shampoo application on days 7 and 14. The video was taken using a camera phone during the first Permethrin 1% shampoo application by Universitas

Katolik Indonesia Atma Jaya Scholl of Medicine and Health Sciences community service team coordinator. One of the team members demonstrated and explained each step necessary to efficiently remove hair parasites from the residents' hair.

After the first treatment (week 4), ten people aged five to 25 y.o. were still suspected of suffering from head lice. A repeat of Permethrin 1% shampoo application was given to these ten people before re-evaluating their condition the following month. After the second treatment, only one person still had *Pediculus capitis*. We coordinated with the orphanage's caretaker to oversee this 11 y.o. female's personal treatment. The last step in eradicating the head lice infestation on this site was to conduct cleaning and disinfection in all of the dorm areas.

### 3. RESULT

Fifty-five children, teenagers, and older adults lived in Yayasan Griya Asih Orphanage from around October until December 2022. There were more males (n = 44) than females (n = 11), ages ranging from five to 26 y.o. Detailed information on Yayasan Griya Asih Orphanage's residents is presented in Table 1.

This first activity involved ten first-year medical students and one faculty member. Six medical students helped to apply permethrin shampoo. Two medical students held a puppet show containing information on head lice and easy personal hygiene measures that the children could follow to improve the treatment's success rate and prevent future relapses. The rest of the students lead a health education activity for the older kids in this orphanage regarding the same topic. Older kids were instructed to apply the permethrin 1% shampoo and comb their hair correctly to increase the chance of getting all the adult and egg-form parasites off their hair. At the end of the activity, 55 hair towels, nit combs, bed sheets, and pillowcases were donated to Yayasan Griya Asih Orphanage. Residents were instructed not to share these items with others to prevent re-infection.

Initial assessment of the head lice infestation showed that all Yayasan Griya Asih Orphanage residents had head lice in various forms (egg, nymph, and adult forms). All of the male residents had mild infestation (one to five lice), but two residents had severe (11-20 lice) *Pediculus capitis* infestation. Four of the female residents had moderate (six to ten lice) infestation. In comparison, seven had severe infestation, and one of which had very severe (more than 20 lice) *Pediculus capitis* chronic infection (Meinking et al., 2013).

**Table 1.** Characteristics of Yayasan Griya Asih Orphanage Residence (n = 55 people)

Characteristic (Age)	Gender		Total
	Male	Female	
5 – 13 y.o.	13 (23.6%)	8 (14.5%)	21 (38.1%)
14 - 20 y.o.	26 (45.4%)	2 (3.7%)	27 (49.1%)
>20 y.o.	5 (9%)	1 (1.8%)	6 (10.8%)
<b>Total</b>	<b>44 (80%)</b>	<b>11 (20%)</b>	<b>55 (100%)</b>



Further, the volunteer had difficulty removing the parasites as the nits were tightly embedded in the severe child's hair strands. None of the children showed signs of pyoderma on their scalps, alopecia, or any systemic symptoms such as fever, malaise, irritability, and lymphadenopathy. These findings showed that the severity of head lice infestation at Yayasan Griya Asih was relatively mild clinically, yet the level of infestation was moderate to very severe.

After the first Permethrin 1% treatment, ten people still showed signs of *Pediculosis capitis*. Nine out of those ten people were aged 5-13 y.o. (seven females and two males), while one person was a 25 y.o. male (Figure 2). Another pulsed dose of permethrin 1% shampoo was given on the second activity, targeting specific people who still showed signs of head lice infestation. Four first-year medical students (different from the first activity) and two faculty members helped with the permethrin 1% application, combing, and personal education in this activity. The educational content was similar to the first activity. However, the delivery method was changed to one-on-one instead of one-to-many in the form of private, personalized instruction to improve the children's understanding of the topic and aid with the treatment.

The room arrangement at Yayasan Griya Asih Orphanage was assessed during the second activity. Several rooms had mites and traces of head lice eggs on and around the beds in several rooms. Considering that head lice could be easily transferred from one person to another, it was decided that thorough cleaning and disinfecting measures of the rooms and mattresses were necessary to completely eradicate the head infestation on this site. All bed mattresses were washed, vacuumed, and disinfected after the second activity. Pest control was also performed in the entire dorm area. A professional cleaning and disinfecting agency was hired to perform deep cleaning during the second week of December 2022 (Figure 3). In the third activity, the team visited Yayasan Griya Asih orphanage to monitor the head lice situation; only one child still had head lice. Nevertheless, this child had the worst head lice infestation compared to the others and

was required to prolong treatment to altogether remove the parasites (Figure 4). The caretaker was asked to keep up with her Permethrin 1% treatment until she completely healed and instructed her not to share her personal effects with others to prevent re-infection.

After the third activity, Universitas Katolik Indonesia Atma Jaya team considered that the efforts in eradicating head lice infestation at Yayasan Griya Asih Orphanage were quite successful, with only one person who required further monitoring. The caretakers and other older residents at



Figure 2 . First head lice eradication activity (October 16<sup>th</sup>, 2022) : Permethrin 1% shampoo application for children aged 5-13 y.o.



Figure 3 . Cleaning and disinfecting Griya Asih Orphanage's dorm area (December 12<sup>th</sup>-16<sup>th</sup>, 2022)

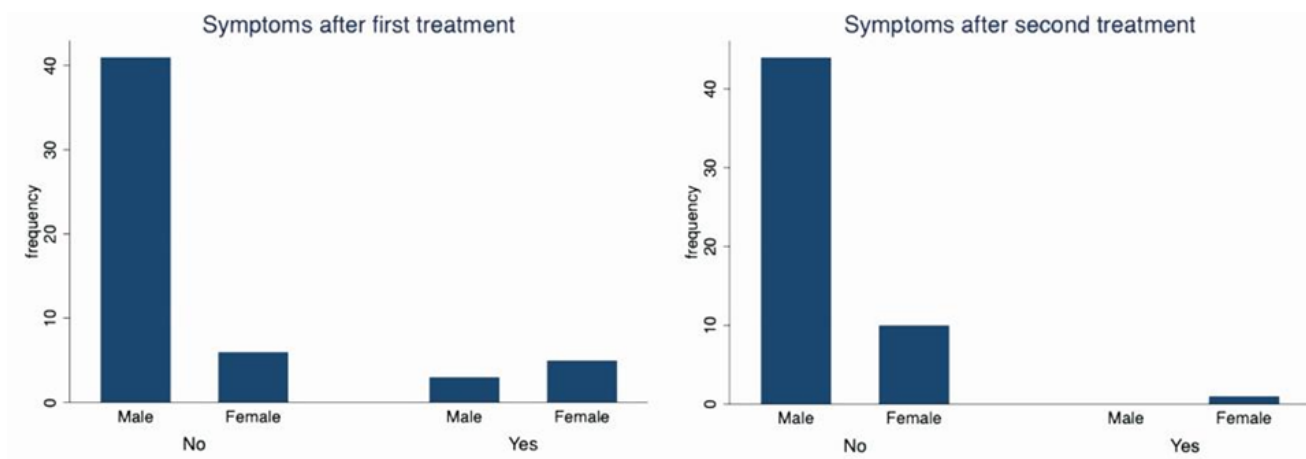


Figure 4 . The number of patients with symptoms after the first and second treatments

Yayasan Griya Asih Orphanage were asked to continue maintaining personal and communal hygiene, especially hair hygiene, to prevent future and recurrent infections.

The rooming arrangement in Yayasan Griya Asih Orphanage, where around eight to ten people were sharing one bedroom with younger children sharing one bed, was indicated as a significant risk factor for head lice (re)infection that might interfere with our efforts to eradicate head lice infestation in this place (Gharsan et al., 2016; Maryanti & Lestari, 2020; Maryanti et al., 2018; Massie et al., 2020). This situation prompted us to consider that everyone who lived in this orphanage had *Pediculosis capitis* and provided treatment and other measures to prevent re-infection, such as changing the bedding of each bed for all residents.

After the first treatment, 46 out of 55 people (83,6%) showed no signs of *Pediculosis capitis*. This indicates that the Permethrin 1% treatment effectively eradicates *Pediculosis capitis* (Maryanti & Lestari, 2020). Further, this also indicates that the residents adhered to our instruction to repeat the treatment on days 7 and 14, maintain their hygiene, keep their hair clean, and cease towel and hair combs sharing behaviour (Castelletti & Barbarossa, 2020; Ganesan, H., & Damayanti, P. A. A., 2017; Gharsan et al., 2016; Maryanti & Lestari, 2020). Ultimately, this finding suggested that we successfully improved Griya Asih residents' awareness and understanding of *Pediculosis capitis* and ways to prevent future re-infection. People living in community group homes typically have limited personal possessions and tend to share items. Hence, a new towel, nit combs, and bedding were provided for each residence to aid them in establishing a new, healthier behaviour that helps in breaking the transmission chain of head lice infection (Gharsan et al., 2016; Maryanti & Lestari, 2020; Nutanson et al., 2008).

Seven out of ten people still have head lice infection after the first treatment were females, and nine out of ten were aged 5-13 y.o. This is in accordance with the research that states females (Lye et al., 2017; Maryanti & Lestari, 2020; Maryanti et al., 2018) aged 5-13 y.o. are more at risk to suffer from head lice infection (Lye et al., 2017; Maryanti & Lestari, 2020; Maryanti et al., 2018; Nutanson et al., 2008). Females are more at risk because they tend to have long hair and have more close contact with each other, making it easier to transmit the disease (Lye et al., 2017; Maryanti & Lestari, 2020; Maryanti et al., 2018). Children aged 5 to 13 y.o. have a higher risk of getting *Pediculosis capitis* due to their tendencies to play as a group, increasing the risk of infection as there are more opportunities for the parasites to leap from one host to another when they come to close contact during their play (Lye et al., 2017; Nutanson et al., 2008).

Interestingly, despite the shared rooming arrangement at Yayasan Griya Asih Orphanage, head lice infestations were still successfully contained to a minimum level. As evidence, four out of the ten people who still showed signs of *Pediculosis capitis* did not re-infect their roommates. Each of these four children sleeps in different rooms, but

none of their roommates complained of itchiness on their scalp or other signs of *Pediculosis capitis*. This might suggest that one's awareness of how head lice infection is transmitted and knowledge to safeguard themselves from the infection played significant roles in eradicating head lice infestation in community group home settings.

To eradicate head lice infection in Yayasan Griya Asih Orphanage, we also cleaned and disinfected their beds and sprayed disinfectant throughout each bedroom to kill any possible parasites that may cause future head lice re-infection. During the room inspection on the second activity, evidence of adult and egg forms of *Pediculus humanus capitis* and other bed parasites was found. An adult *Pediculus humanus capitis* can survive up to 30 hours away from the host's body, while the eggs can survive up to one week (Bartosik, K. et al., 2022). Because this was not the first head lice infestation at Griya Asih, additional effort was deemed necessary to properly break the transmission chain of head lice infection (Mitriani et al., 2017).

After the second treatment, only one female aged 11 y.o. still suffered from head lice infection. Among everyone, she had the worst case of *Pediculus capitis*. The eggs were tightly sticking to her hair, and we could not properly remove all parasites from her hair during our first and second treatments. This condition typically appears on chronic head lice infection, confirming that the head lice infestation had been going on for a while in this place. Secondary infection might develop in some cases of *Pediculosis capitis* (Bartosik, K. et al., 2022), causing hair clumps due to pus and dried crust (Riswanda & Arisandi, 2021). The parasites may sometimes resist Permethrin 1% shampoo due to prolonged application. Nevertheless, a significant improvement in her hair condition after the first and second treatments; hence we decided to repeat another dose of Permethrin 1% shampoo and re-evaluate her condition the following month.

## 4. CONCLUSION

Head lice infestation screening is essential in a crowded environment such as orphanages and dorms. Application of Permethrin 1% pulsed dose (days 0, 7, and 14) for all the residents with head lice infestations in this kind of group home environment. The treatment must be evaluated at the end of each Permethrin 1% application cycle (around week 3-4) to decide whether a repeated dose of the same pediculicide was necessary or if another type of pediculicide is warranted depending on the severity and responsiveness to treatment. This case study showed that a minimum of two pulsed doses of Permethrin 1% shampoo application was necessary to eradicate a chronic, moderate to severe *Pediculosis capitis* infestation in a group home environment. In addition, personalized health education activities and pest control proved to be effective in breaking the disease transmission chain and eradicating head lice infestation specifically in chronic and severe cases of head lice infection; hence, close monitoring of treatment progress is essential to ensure the eradication of head lice infestation in crowded dwellings.

## ACKNOWLEDGMENT

We would like to thank the people who donated money, Permethrin 1% shampoo, towels, nit combs, and beddings to our cause in eradicating head lice infestation in Yayasan Griya Asih Orphanage.

## CONFLICT OF INTERESTS

All authors declare that there was no conflict of interest in this community service program.

## REFERENCES

- Bartosik, K., Janczaruk, M., Zajac, Z., Sedzikowska, A., Kulisz, J., Woźniak, A., Jaształ-Kniażuk, A., Kulbaka, E., & Tytuła, A (2022). Head lice infestation in schoolchildren, in Poland: Is there a chance for change? *Journal of Clinical Medicine*, 11(3), 783. <https://doi.org/10.3390/jcm11030783>
- Benca, J. (2012). Infectious diseases in orphanages in South-east Asia. *International Journal of Infectious Diseases*, 16. <https://doi.org/10.1016/j.ijid.2012.05.020>
- Castelletti, N. & Barbarossa, M. V. (2020). Deterministic approaches for head lice infestations and treatments. *Infectious Disease Modelling*, 5, 386–404. <https://doi.org/10.1016/j.idm.2020.05.002>
- Ganesan, H., Damayanti, P. A. A. (2017). Faktor resiko terjadi infestasi kutu pada anak-anak di panti asuhan. *Intisari Sains Medis*, 8(3), <https://doi.org/10.15562/ism.v8i3.137>
- Gharsan, F. N., Abdel-Hamed, N., Elhassan, S. a. a. M., & Gubara, N. G. a. R. (2016). The prevalence of infection with head lice *Pediculus humanus capitis* among elementary girl students in Albaha Region-Kingdom of Saudi Arabia. *International Journal of Research in Dermatology*, 2(1), 12-17. <https://doi.org/10.18203/issn.2455-4529.intjresdermatol.20161426>
- Hardiyanti, N. I., Kurniawan, B., Mutiara, H., & Suwandi, J. F. (2015). Penatalaksanaan *Pediculosis capitis*. *Jurnal Majority*, 4(9), 47–52. <https://juke.kedokteran.unila.ac.id/index.php/majority/article/view/1406>
- Kim, D.-H., Son, H.-M., Lee, S. H., Park, M. K., Kang, S. A., Park, S. K., Choi, J.-H., Park, J. H., & Yu, H.-S. (2015). Negligible egg positive rate of *Enterobius vermicularis* and no detection of head lice among orphanage children in Busan and Ulsan, Korea. *The Korean Journal of Parasitology*, 53(4), 497-499. <https://doi.org/10.3347/kjp.2015.53.4.497>
- Lye, M. S., Tohit, N. M., & Rampal, L. (2017). Prevalence and predictors of *Pediculosis capitis* among primary school children in Hulu Langat, Selangor. *PubMed*, 72(1), 12–17. <https://pubmed.ncbi.nlm.nih.gov/28255134>
- Maryanti, E., & Lestari, E. (2020). Pendidikan kesehatan dalam rangka menuju panti asuhan bebas pedikulosis kapitis di Kecamatan Siak Hulu Kabupaten Kampar. *Riau Journal of Empowerment*, 3(2). <https://doi.org/10.31258/raje.3.2.97-103>
- Maryanti, E., Lesmana, S. D., & Novira, M. (2018). Hubungan faktor risiko dengan infestasi *Pediculus humanus capitis* pada anak panti asuhan di Kota Pekanbaru. *Jurnal Kesehatan Melayu*, 1(2), <https://doi.org/10.26891/jkm.v1i2.2018.73-80>
- Massie, M. A., Wahongan, G. J. P., & Pijoh, V. D. (2020). Prevalensi infestasi *Pediculus humanus capitis* pada anak sekolah dasar di Kecamatan Langowan Timur. *Jurnal Biomedik*, 12(1), 24-30.
- Meinking, T. L., Mertz-Rivera, K., Villar, M. E., Bell, M. (2013). Assessment of the safety and efficacy of three concentrations of topical ivermectin lotion as a treatment for head lice infestation. *International Journal of Dermatology*, 52(1), 106-112. <https://doi.org/10.1111/j.1365-4632.2012.05629.x>
- Mitriani, S., Rizona, F., & Ridwan, M. (2017). Hubungan pengetahuan dan sikap *Pediculosis capitis* dengan perilaku pencegahan *Pediculosis capitis* pada santri asrama Pondok Pesantren Darussalam Muara Bungo. *Jurnal Keperawatan Sriwijaya*, 4(2).
- Nutanson, I., Steen, C. J., Schwartz, R. A., & Janniger, C. K. (2008). *Pediculus humanus capitis*: An update. *Acta dermatovenerologica alpina, Pannonica, Et Adriatica*, 17(4), 147–154.
- Panti Asuhan Griya Asih. (2020). *Profil Panti Asuhan Griya Asih*. <http://pa-griyaasih.epizy.com/?i=1>
- Restapaty, R., Hidayati, R., & Sayakti, P. I. (2019). Pemberian edukasi kesehatan rambut dan kulit kepala pada penghuni Rumah Yatim Ar-Rahmah Banjarbaru Kalimantan Selatan. *Journal of Science and Social Development*, 2(2), 110–116.
- Riswanda, J., & Arisandi, Y. (2021). *Pediculosis capitis*. Qiara Media.
- Rumampuk, M. V. (2014). Peranan kebersihan kulit kepala dan rambut dalam penanggulangan epidemiologi *Pediculus humanus capitis*. *Jurnal Ners*, 9(1), 35–42.
- Suweta, N. P. T. B., Swastika, I. K., & Sudarmaja, I. M. (2021). Prevalensi *Pediculosis capitis* dan faktor risiko infestasinya pada anak di SD No. 6 Darmasaba, Kecamatan Abiensemal, Kabupaten Badung. *Jurnal Medika Udayana*, 10(6), 54–60.