

Antibiotics Combination Effects of Tylosin and Enrofloxacin on Liver and Renal Functions of Broiler

Ida Fitriana,¹ Arimurti Chusnul Chotimah¹, *Agustina Dwi Wijayanti¹, Yuli Purwandari K²,
Anggi Muchtar Pratama¹

¹Department of Pharmacology, Faculty of Veterinary Medicine, Universitas Gadjah Mada

²Department of Pathology, Faculty of Veterinary Medicine, Universitas Gadjah Mada

*Corresponding author: tynabdy@ugm.ac.id

Received: March 20, 2019, Accepted: July 4, 2019, Published: February 26, 2020

Abstracts

The combination of tylosin and enrofloxacin antibiotics is a new drug that is intended as a medicated feed in the world of poultry. Therefore before being marketed in the community this drug needs to be tested first. The purpose of this study was to find out the effects of tylosin and enrofloxacin as combination antibiotic on liver and renal functions of broiler chickens.

Fourty (40) broilers maintained in the animal cages from Day Old Chick (DOC) and has given feed and water ad libitum. Broilers were divided into four groups each containing 10 chickens. Group I was treated with combination of tylosin and enrofloxacin antibiotics 0,5 gram in 2 liters of drinking water, group II was treated at dose of 1 grams in 2 liters of drinking water, group III was treated at dose of 2 grams in 2 liters of drinking water, while group IV as a control without antibiotics treatment. The treatment of combination antibiotics was carried out 7 days. Blood samples were collected at the 30th day. For examination of Alanine Transaminase (ALT) and creatinine concentration. Liver and renal. sample for histopathological examination.

The results of the statistical analysis showed that combination antibiotics of tylosin and enrofloxacin had no significant effect on ALT and creatinine concentration of broiler chickens. The highest concentrations of ALT and creatinine were Group II ($20,333 \pm 18,768$ U/L) and group III (0.4 ± 0 mg/dL), respectively. Histopathological changes of liver and renal organs showed that all groups were normal and there is no pathology. Based on this study can be concluded that the combination of tylosin and enrofloxacin antibiotics for 7 days did not affect to function of liver and renal broiler.

Key words; tylosin, enrofloxacin, ALT, creatinine, broiler.

Introduction

Poultry meat as a source of animal protein and its needs continues to increase due to the cheapest and easiest type of meat in various countries¹. One of the poultry that can produce meat is broiler. Broilers are superior chicken breeds that have high productivity, especially in producing meat that is able to grow quickly so that it can produce meat in a relatively short time (5-6 weeks)².

However, not all broiler farms are successful, the failure of farmers also often occurs. Constraints that most often cause failure of farmers are management errors that result in an environment that is not conducive and cause various kinds of bacteria that cause disease³. During this time, antibiotics are used for treatment and as feed

additives to be free from disease so that the growth is not hampered. However, the use of antibiotics are not in accordance with excessive doses and prolonged periods can cause residues in organ tissues. Another effect can cause allergic reactions, resistance and poisoning so that it is quite dangerous for human health⁴. Therefore, its use is prohibited by the government⁵.

For the treatment of poultry, the government recommends using medicated feed⁶. Medicated feeds are feed for animals that contain animal drugs. The combination of tylosin and enrofloxacin antibiotics is a new drug that is intended as a medicated feed in the world of poultry. Therefore before this drug is circulated it needs to be tested first. Preclinical testing is a test requirement for

prospective drugs. Based on this test information was obtained about efficacy or pharmacological effects, pharmacokinetic profiles and toxicity of prospective drugs. Only by using whole animals can it be known whether the drug has a toxic effect on the dosage of medication or is safe to use⁷. This study aimed to determine the combination effect combination of tylosin and enrofloxacin antibiotics on liver and renal function of healthy broiler.

Materials and Methods

The materials. Experimental animals were broiler chickens. This study used Newcastle Disease vaccine, and Infectious Bursal Disease vaccine. The drugs used in this study are pharmaceutical veterinary formulation of antibiotics combination of tylosin tartate and enrofloxacin.

Ethical approval. This experiment has received approval from the Ethical Clearance Commission of Faculty of Veterinary Medicine, Universitas Gadjah Mada, Yogyakarta, Indonesia, with number: 0027 / EC – FKH / Int. / 2018.

Animal and experimental design. Day Old Chick (DOC) broiler chickens were maintained and adapted in the cages with a rice husk litter system. Chickens given feed and drink in ad were done and Infectious Were Bursal Disease (Gumboro). Broiler chickens were are divided into four groups, each group containing 10 chickens. Group I was treated with combination of tylosin and enrofloxacin antibiotics at a dose of 0.5 gram in 2 liters of drinking water, group II was treated at a dose of 1 gram in 2 liters of drinking water, group III was treated at a dose of 2 grams in 2 liters of drinking water, while group IV without antibiotics treatment as a control. The administration of antibiotics combinations of tylosin and enrofloxacin is carried out for 7 days, on the 18th to 24th day.

Collection and examination of samples. Blood samples from all groups of chickens was carried out on the 30th day. Blood samples were taken through the brachial vein. Then centrifugation at 3000 rpm for 10 minutes. Samples were stored in a refrigerator at 4°C until examination of blood samples. Blood sample were used for examination of Alanine Transaminase

(ALT) and creatinine concentration using Semi-Auto Chemistry Analyzer Caretium NB-201. The layers were euthanized by intracardiac administration of saturated MgSO₄ solution⁸. A thorough post-mortem-examination of all dead layers was carried out. Liver and renal organs sample were collected and fixed with neutral buffer formalin. Organ sample were processed with paraffin-embedded method and visualized by using Hematoxyllin-Eosine stain.

Statistical analyses. Alanin Transaminase and creatinine concentration were analyzed quantitatively by One Way ANOVA test. Statistical calculations used SPSS v.16 (SPSS, Chicago, IL). Histology of liver and renal sample were analyzed qualitatively.

Result

Fig. 1 showed that group II had the highest ALT level, which was an average of $20,333 \pm 18,768$ U/L and the lowest was group I with an average of 9.3 ± 0.8 U/L. The highest creatinine level in group III (0.4 ± 0 mg/dL) while the lowest in group II (0.233 ± 0.153 mg/dL) (Figure 2). The results of statistical testing explained that ALT and creatinine in broiler blood serum in the group combination of tylosin and enrofloxacin antibiotics did not differ significantly to the control group. Histological observation of liver and renal organs showed that all groups were normal and there is no changes (Fig. 3)

Discussion

Elimination of drugs from the body involves two processes: metabolism (biotransformation) and excretion. In general, drugs eliminated by the liver can increase liver function disorders and this preference should be given for the use of drugs that have bactericidal action⁹. Fig. 1 showed that ALT levels in the combination group of tylosin and enrofloxacin with a dose of 1 gram in 2 liters of drinking water ($20,333 \pm 18,768$ U/L) and 2 grams in 2 liters of drinking water ($15,567 \pm 2,051$ U/L) were higher than the control group ($11,8 \pm 0,8$ U/L). Based on the results of observations of histopathological results, showed that broiler liver did not change pathology (Fig. 3). This is in accordance with cafe et al. (2012) that the biochemical parameters of broiler blood at the age of 28-35 days were 21.83 – 19.33 IU / L¹⁰.

Alanine transaminase is a relatively specific enzyme as an indicator of acute liver cell damage and pathological manifestations of liver failure. When damage occurs, ALT is released from liver cells into the bloodstream, so that an increase in concentration can indicate damage to the liver¹¹. According to Raini (2016) an increase in liver enzymes such as ALT, AST and alkaline phosphatase occur between 1-3% in patients receiving ciprofloxacin, norfloxacin, and ofloxacin¹². The fluoroquinolone mechanism induces hepatotoxicity through the formation of oxidative radicals in the liver. Tylosin is metabolized by the cytochrome P450-3A pathway in the liver and then excreted through feces and bile¹³. This will increase the load on the network so that it can cause damage to the network¹⁴.

The results of this study showed that creatinine levels in all groups of chickens did not differ significantly between groups and according to the results of histopathological examination of the kidneys in all groups there were no pathological changes (Fig. 3). This means that the combination of tylosin and enrofloxacin antibiotics did not affect kidney function. This is also in accordance with Hochleitner's (2013) study that broiler creatinine concentrations were 0.10 - 0.40 mg/dL¹⁵. Normally creatinine production is relatively constant and is slightly affected by catabolism in food proteins or tissues. Severe kidney damage can cause an increase in creatinine levels, especially if the glomerular filtration rate decreases. Increased creatinine levels are also associated with peritonitis, septicemia, kidney trauma and nephrotoxic drugs¹⁵. Tylosin is excreted through feces and bile¹³, while enrofloxacin is excreted through urine and feces in high concentrations¹⁶. This antibiotics has the risk of inducing kidney damage if the given dose is excessive. However, the antibiotic used in this study was safe to use as a medicated feed.

Conclusion

Based on the results of the study, it can be concluded that the administration of a combination of tylosin and enrofloxacin antibiotics for 7 days did not cause damage to the liver and kidney function of the broiler.

Conflict of interest. The authors declare that they have no competing interests

Acknowledgments. This research was supported by research grant number 1062/J01.1.22/HK4/2018 and collaboration between the Faculty of Veterinary Medicine, Universitas Gadjah Mada with Tekad Mandiri Citra Company.

References

1. Tabbu, C.R. 2016. *Manajemen Kesehatan Ayam*. Kanisius. Yogyakarta. 1, 24-26.
2. Ardana, I.B.K. 2009. *Ternak Broiler*. Swasta Nulus. Denpasar.
3. Rasyaf, Muhammad. 2010. *Panduan Beternak Ayam Pedaging*. Penebar Swadaya. Jakarta.
4. Yuningsih, 2004. Keberadaan Residu Antibiotika dalam Produk Peternakan (Susu dan Daging). *Lokakarya Nasional Keamanan Pangan Produk Peternakan*. Bogor: Balai Penelitian Veteriner. 48-55.
5. Anonim. 2017. Peraturan Menteri Pertanian No. 14 Tahun 2017 tentang Klasifikasi Obat Hewan. Kementrian Pertanian Republik Indonesia: Jakarta
6. Anonim. 2018. Keputusan Direktur Jenderal Peternakan dan Kesehatan Hewan No.09111/KPTS/ PK.350/F/09/2018, tentang Petunjuk Teknis Penggunaan Obat Hewan dalam Pakan untuk Tujuan Terapi. Direktorat Jendral Peternakan dan Kesehatan Hewan Republik Indonesia: Jakarta
7. Forth, W., D. Henschler, W. Rummel, U. Foerstermann und K. Stark. 2001. *Allgemeine und spezielle Pharmakologie und Toxikologie*. Urban & Fisher: Muenchem
8. Matin, M.A., Islam, M.A., and M.M. Khatun, 2017. Prevalence of *colibacillosis* in chickens in greater Mymensingh district of Bangladesh. *Veterinary World*, 10(1): 29–33. DOI: 10.14202/vetworld.2017.29-33; PMID: PMC5301176
9. Giguere, S. *Antimicrobial Therapy in Veterinary Medicine*. 5th Edition. Wiley Blackwell. Iowa.
10. Café, M.B., Rinaldi, F.P., Morais, H.R., et al. 2012. Biochemical Blood Parameters of Broilers At Different Ages Under Thermoneutral Environment. *World's Poultry Science Journal*: 143-146

11. Toghyani, M., Gheisari, A., Ghalamkari, G., Eghbalsaied. 2011. Evaluation of Cinnamon and Garlic as Antibiotic Growth Promotor Substitutions on Performance, Immune Response, Serum Biochemical and Haematological Parameters in Broiler Chicks. *Livestock Sciences* 138: 167-173.
12. Raini, M. 2016. Antibiotik Golongan Fluorokuinolon: Manfaat dan Kerugian. *Media Litbangkes, Vol. 26 No.3.* 163-174.
13. Soliman, A.M. dan Sedeik, M., 2016. Pharmacokinetics and Tissue Residues of Tylosin in Broiler Chickens. *Pharmacology & Pharmacy* 7(01): 36.
14. Elbayoumi, K.M., Girh, Z.M.S., Amer, A.M., Hassan, E.R., Amer, M.M. 2017. Clinicopathological Changes in Sera of Broiler Chicken Given Antibacterial and Or Prebiotics. *Research Journal of Pharmaceutical, Biological and Chemical Sciences* 8 (2).
15. Hochleithner, M. 2013. Chapter 11: Biochemistries. In: *Avian Medicine, Principles and Application*. Ritchie, B.W., Harrison, G.J., Harrison, L.R. Winger Publishing. Florida: 223-245.
16. Jelena, P., Baltic, M., Cupic, V., Stefanovic, S., Dragica, S. 2006. Residues of Enrofloxacin And Its Metabolite Ciprofloxacin In Broiler Chickens. *Acta Vet. (Beograd)*. 56: 497-506.

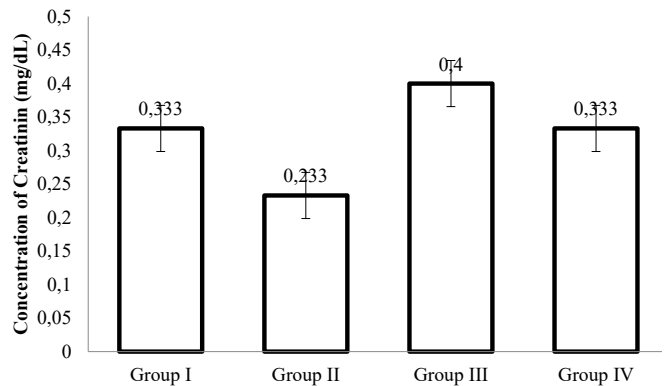


Figure 2. Concentration of Creatinine (mg/dL) (value = means ±SD). Group I was treated with combination of tylosin and enrofloxacin antibiotics 0,5 gram in 2 liters of drinking water, group II was treated at dose of 1 grams in 2 liters of drinking water, group III was treated at dose of 2 gram in 2 liters of drinking water, and group IV as a control, dringing water without antibiotics treatment.

Figure

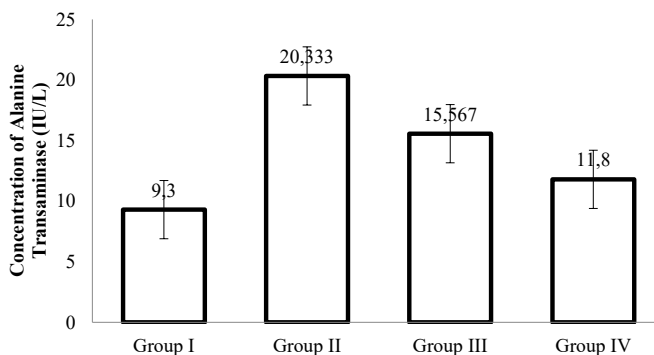


Figure 1. Concentration of Alanine Transaminase (IU/L) (value = means ±SD). Group I was treated with combination of tylosin and enrofloxacin antibiotics 0,5 gram in 2 liters of drinking water, group II was treated at dose of 1 grams in 2 liters of drinking water, group III was treated at dose of 2 gram in 2 liters of drinking water, and group IV as a control, dringing water without antibiotics treatment.

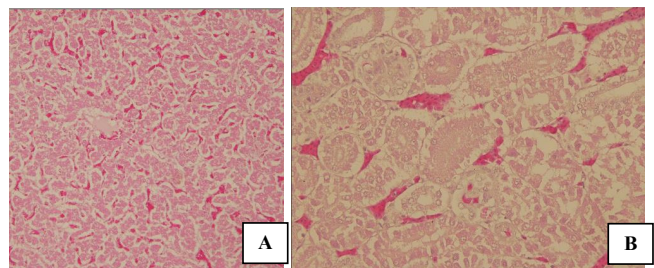


Figure 3. Histological observation of liver (A) and renal organs (B) showed that all groups were normal and there is no histopathological changes