



## Coronavirus disease 2019 (COVID-19) related stroke incidence: a case series

Hanindia Riani Prabaningtyas\*, Maria Yosita Ayu Hapsari, Stefanus Erdana Putra, Muhammad Hafizhan, Diah Kurnia Mirawati, Pepi Budianto, Subandi Subandi, Rivana Danuaji

Department of Neurology, Faculty of Medicine, Universitas Sebelas Maret, Surakarta, Indonesia

### ABSTRACT

Submitted: 2022-02-23  
Accepted : 2022-07-21

Coronavirus disease 2019 (COVID-19) can cause systemic and respiratory symptoms. Acute respiratory distress syndrome (ARDS), anemia, acute heart injury, secondary infection, and stroke are the complications of COVID-19. Age, oxidative stress, endothelial dysfunction, inflammatory status, vascular risk factors, and hypoxemia are risk factors for stroke associated with COVID-19. In this case report, two cases of COVID-19 complicated by stroke and other thromboembolic diseases were discussed. Case 1: a 46-year-old man presented with right extremities weakness, dysarthria, cough, colds, chest pain radiating to left upper extremity. He was diagnosed with moderate COVID-19, with complication of embolic stroke and myocardial infarction. After administration of IV furosemid and recombinant tissue plasminogen activator (rTPA), his condition improved, and he was discharged from our facility. Case 2: a 54-year-old woman presented with a decreased level of consciousness, skin discoloration, tenderness on her left calf, cough, fever, and shortness of breath. She was diagnosed with moderate COVID-19 with a complication of thrombotic stroke and deep vein thrombosis (DVT). She was treated with rTPA, IV citicoline, and fondaparinux for 5 days. In conclusion, COVID-19 carries a risk of thromboembolic complication. COVID-19 patients have a higher risk of bleeding, therefore, medications, particularly anticoagulant, should be administered with more caution.

### ABSTRAK

*Coronavirus disease 2019 (COVID-19) dapat menyebabkan gejala sistemik dan gejala pernafasan. Komplikasi yang bisa dialami pasien dengan COVID-19 adalah sindrom distres napas akut, anemia, cedera jantung akut, infeksi sekunder, dan stroke. Faktor risiko terjadinya stroke pada COVID-19 meliputi usia, stres oksidatif, disfungsi endotel, status inflamasi, faktor risiko vaskular, dan hipoksemia. Dalam laporan kasus ini, kami membahas dua kasus COVID-19 yang mengalami komplikasi stroke dan penyakit tromboembolik lainnya. Kasus 1: laki-laki 46 tahun datang dengan kelemahan anggota gerak tubuh bagian kanan, disartria, demam, dan nyeri dada yang menjalar ke tangan kiri. Pasien didiagnosis COVID-19 derajat sedang dan mengalami komplikasi stroke emboli serta infark miokardium. Setelah pemberian furosemid dan *recombinant tissue plasminogen activator* (rTPA) IV, kondisi klinis pasien membaik dan kemudian pulang dari rumah sakit. Kasus 2: wanita 54 tahun datang dengan penurunan kesadaran, perubahan warna kulit dan bengkak pada betis kanan, batuk, demam, dan sesak. Pasien didiagnosis dengan COVID-19 derajat sedang, dengan komplikasi stroke trombotik dan trombosis vena dalam. Pasien dirawat dengan rTPA, citicolin IV, dan fondaparinux selama 5 hari. Kesimpulan, COVID-19 memiliki risiko komplikasi tromboembolik. Pasien COVID-19 juga rentan mengalami perdarahan, sehingga diperlukan kehati-hatian dalam pemberian terapi, terutama antikoagulan.*

### Keywords:

COVID-19;  
stroke;  
SARS-CoV-2;  
risk factors;  
thromboembolic

## INTRODUCTION

Coronavirus disease 2019 (COVID-19) is an emerging disease mainly manifested as respiratory symptoms. However, it also causes systemic symptoms, with approximately 36.4% of patients experiencing neurological manifestations, including headache, impaired consciousness, and paresthesia. These symptoms are more common in patients with severe cases, compared to those with mild or moderate COVID-19.<sup>1</sup> Several studies hypothesize that severe acute respiratory syndrome coronavirus 2 (SARS-CoV-2), the causative agent of COVID-19, binds to angiotensin converting enzyme 2 (ACE2) receptors on brain tissue.<sup>2</sup>

Coronavirus disease 2019 also causes coagulopathy, inflammatory cascade, hypoxia, and vascular endothelial dysfunction, which increase the risk of thrombus formation. These processes are thought to be responsible for thrombotic complications of COVID-19, including deep vein thrombosis (DVT), pulmonary embolism (PE), myocardial injury, and ischemic stroke. Compared to other thrombotic complication of COVID-19, stroke is considered rare.<sup>1,3,4</sup> In this case series, two cases of COVID-19 infection with complication of stroke, one of which also had myocardial injury, and DVT on another case were presented. In-depth discussion of coagulopathy and thrombotic complication of COVID-19 were also provided.

## CASES

### Case 1

A 46-yo male, with known history

of hypertension, dyslipidemia, and ischemic stroke in 2018, presented to the emergency department with sudden worsening of left upper and lower extremity weakness and worsening dysarthria for 4 h before admission. He also had a cough, cold, chest pain radiating to left upper extremity, and shortness of breath for 3 d. A screening test with rapid COVID-19 antigen was positive, and polymerase chain reaction (PCR) test confirmed the COVID-19 diagnosis.

In the emergency department, he was somnolent with a Glasgow Coma Scale (GCS) E4V5M4, elevated blood pressure (171/92 mmHg), tachycardia (heart rate 122 bpm), tachypnea (respiratory rate 26 bpm), elevated temperature (37.9°C), and hypoxia (SpO<sub>2</sub> 93% on room air). Coarse crackles were found throughout both lung fields. Extremities drifted to the left on physical examination, indicating left sided weakness, with normal tone in all extremities. Physiological reflexes increased, and left Babinski reflex was observed, indicating upper motor neuron (UMN) lesion.

Blood work revealed electrolyte imbalance (calcium ion 0.95 mmol/L), coagulopathy (D-dimer 3044.59 ug/L), dyslipidemia (total cholesterol 256 mg/dL), and increased cardiac biomarker (HS troponin I 60 ng/L). A chest X-ray revealed bronchopneumonia, and a head CT scan showed hypodensity on the right pons, thalamus, and posterior limb of internal capsule, supporting the diagnosis of multiple lacunar infarction (FIGURE 1). An electrocardiography (ECG) study showed ST elevation on lead II, III, and aVF, indicating inferior ST elevation acute coronary syndrome (STE-ACS).

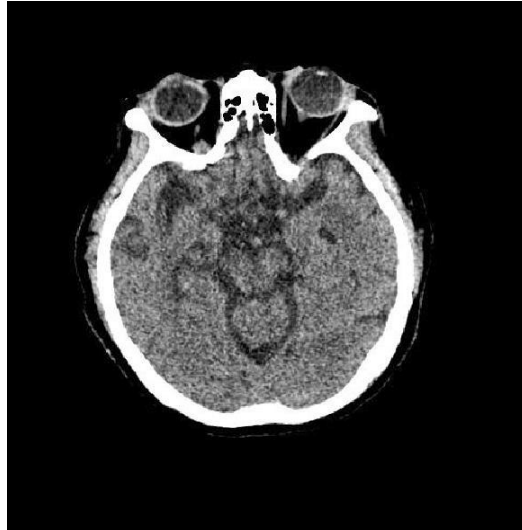

FIGURE 1. Multiple lacunar infarction on pons, thalamus, and posterior limb of internal capsule

A diagnosis of moderate COVID-19 with complication of embolic stroke and myocardial infarction was made, and IV furosemide 20 mg q.d. was administered for pulmonary edema. Recombinant tissue plasminogen activator (rTPA), a thrombolytic agent, is administered in doses of 40 mg, 10% as an initial IV bolus over one min and the remainder infused over 60 min. Citicoline is given intravenously in doses of 250 mg twice daily as a neuroprotectant to stabilize membrane permeability. Hypertension was managed with oral carvedilol 6.25 mg b.i.d., and oral ramipril 5 mg q.d., targeting 160/90 mmHg on 6 h. IV ciprofloxacin 400 mg b.i.d., IV vitamin D 2000 IU q.d., IV paracetamol 500 mg q.i.d., oral favipiravir 600 mg b.i.d., and oral ambroxol 30 mg t.i.d. were administered following the Indonesian recommendation for COVID-19 infection. Evaluation PCR test on day 8 and 9 of treatment showed negative COVID-19 results, and she was discharged from isolation room. She then moved to non-infection ward for further evaluation. After 11 d of treatment, she showed improvement of left extremities

weakness, and she was discharged from our facility.

## Case 2

A 54-yo female was brought to the emergency department with decreased level of consciousness, skin discoloration, and tenderness on her left calf. For four days before admission, she had a cough, fever, and shortness of breath.

On physical examination, a decreased level of consciousness with GCS E4V4M5, elevated blood pressure (143/82 mmHg), tachycardia (heart rate 108 bpm), tachypnea (respiratory rate 22 bpm), elevated temperature (38.1°C), hypoxia (SpO<sub>2</sub> 94% on room air), and coarse sounds in both lung fields were observed. On neurological examination, her extremities drifted to the left, indicating lateralization to the left. An increased muscle tone, increased physiological reflexes, and a left Babinski reflex, indicating an UMN lesion were also observed. On palpation, the left Gastrocnemius muscle was swollen, warm, darkened, and the total Well's score was 3, suggesting DVT (TABLE 1).

TABLE 1. Wells' criteria for DVT

Clinical feature	Score
Active cancer, treatment or palliation within 6 mo	0
Bedridden recently >3 d or major surgery within 12 wk	1
Calf swelling >3 cm compared to the other leg, measured 10 cm below tibial tuberosity	1
Collateral (non-varicose) superficial veins present	0
Entire leg swollen	0
Localized tenderness along the deep venous system	1
Pitting edema, confined to symptomatic leg	1
Paralysis, paresis, or recent plaster immobilization of the lower extremity	0
Previously documented DVT	0
Alternative diagnosis to DVT as likely or more likely	0
Total Score	4

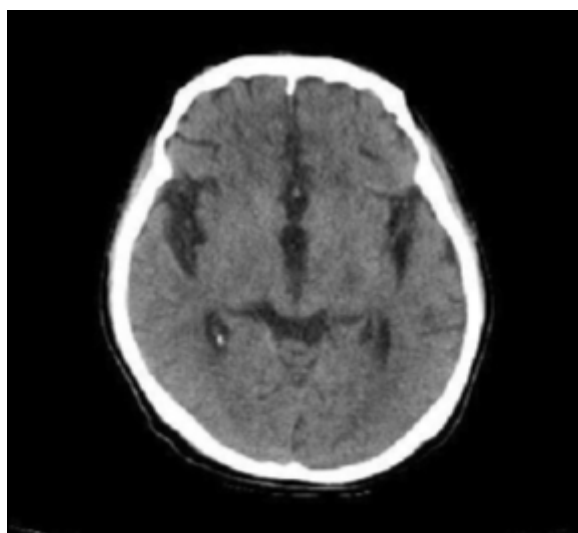


FIGURE 2. Hypodensity lesion in right hippocampus and temporal horn of internal capsule

Laboratory results showed a hypercoagulable state (D-dimer 4,904.43 ng/mL), leukocytosis (leukocytes 16,810/ $\mu$ L, absolute lymphocyte count 1,300/ $\mu$ L, lymphocytes 8.1%, and neutrophils 84.2%). A chest X-ray revealed infiltrate in both lung fields, increased bronchovesicular markings, indicating

bronchopneumonia. A head CT scan revealed a hypodensity lesion in the right hippocampus and temporal horn of the internal capsule, indicating ischemic stroke (FIGURE 2). On ultrasonography study, we found total occlusion of popliteal vein (FIGURE 3).

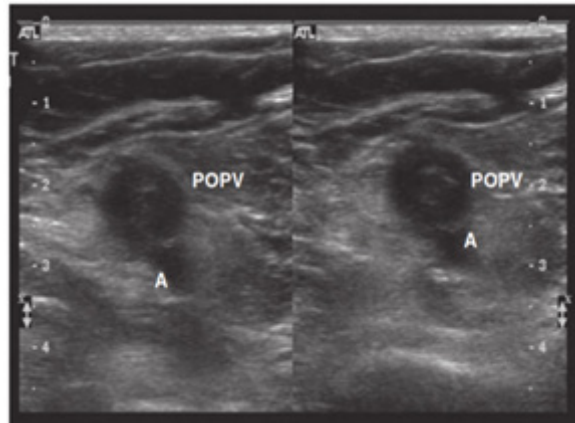


FIGURE 3. Total occlusion of popliteal vein

A diagnosis of moderate COVID-19 with complications of thrombotic stroke and DVT was made. She received 40mg of rTPA, administered as 10% initial IV bolus over 1 min and the remainder infused over 60 min, IV citicoline 250 mg b.i.d., and fondaparinux 2.5 million IU q.d. for 5 d. For the management of moderate COVID-19, she received favipiravir 600 mg b.i.d., IV paracetamol 1 g b.i.d, IV dexamethasone 5 g q.d., and IV ciprofloxacin 400 mg b.i.d. Her level of consciousness improved to E4V3M5 after 5 d of treatment and to E4V5M6 1 d. After her COVID-19 PCR test converted to negative on 8<sup>th</sup> day of treatment. She was transferred to a non-infectious ward. Once she was fully conscious, we observed mild paresis of the left VII and XII nerves, upper limb strength of (555/222), and lower limb strength of (555/222). She was discharged after showing improvement in upper and lower limb strength to (555/333) and (555/333), respectively; also, pain and inflammation on the left calf subsided on 11<sup>th</sup> day of treatment.

## DISCUSSION

As of February 2022, COVID-19 cases reached 392 million, with more than 5.7 million deaths globally. According to epidemiological studies, patients with acute COVID-19 infection are at risk

for thromboembolic complications.<sup>5</sup> DVT is the most common type (around 46%) of thromboembolic complication of COVID-19, followed with pulmonary embolism (24%), myocardial injury (20%), and stroke (1.6%).<sup>6</sup>

In this study, 2 cases of stroke as a complication of COVID-19 were represented. Myocardial infarction occurred in one patient, and DVT in another case were also found. In these cases, thromboembolic complications were observed in moderate COVID-19, rather than severe infection. Neurological complications in COVID-19 infection may result from direct central nervous system infections or abnormalities due to the parainfective process. Several mechanisms have been proposed to explain comorbidities between COVID-19 infection and stroke, including endotheliopathy, hypoxia, and inflammatory cascade.<sup>2,7-9</sup>

A retrospective study from Wuhan, China showed that the incidence of stroke in COVID-19 patients was around 5%.<sup>10</sup> Stroke (especially ischemic stroke) was more common in patients with severe infection than in patients with mild infection (5.7% vs. 0.8%).<sup>11</sup> Stroke and severe COVID-19 share common risk factors, such as hypertension, diabetes, coronary heart disease, and chronic kidney failure.<sup>12</sup> However, COVID-19 patients with thromboembolic complication do not always have classical

risk factors like atrial fibrillation, family history of venous thromboembolism (VTE), or antiphospholipid antibody syndrome. Some COVID-19 patient still develop thromboembolism, even after receiving anticoagulants prophylaxis.<sup>13</sup>

Similar to vascular endothelial dysfunction with sepsis-induced coagulopathy, endotheliopathy appears to contribute to the pathophysiology of microcirculatory changes in SARS-CoV-2 infection. SARS-CoV-2 binds to ACE2 receptors on endothelial cells, and its replication causes inflammatory cell infiltration, endothelial cell apoptosis, and microvascular prothrombotic effects. These alteration by SARS-CoV-2 infection will lead to endothelial cell dysfunction.<sup>14</sup>

Endothelial cell dysfunction due to infection, including SARS-CoV-2 infection, leads to an accumulation of thrombin production and decreased fibrinolysis, creating a hypercoagulable state, and increasing the risk of thromboembolism complication.<sup>2</sup> Proliferation of SARS-CoV-2 in lung tissue causes diffuse alveolar and interstitial edema and exudate, forming a transparent membrane. This process leads to disruption of alveolar gas exchange, which in turn causes hypoxia in the central nervous system and increase in anaerobic metabolism in the mitochondria of neural cells. Acid accumulation as a byproduct of anaerobic metabolism could further lead to cerebral vasodilation, neural cell edema, interstitial edema, obstruction of cerebral blood flow, cellular damage, and apoptosis due to ischemia and congestion.<sup>3</sup> Additionally, hypoxia that occurs in severe COVID-19 infection can trigger thrombosis, not only by increasing blood viscosity but also by hypoxia-inducible transcription factor-dependent pathways.<sup>4,8</sup>

Coronavirus disease 2019 infection is also associated with proinflammatory cytokines that can induce mononuclear and endothelial cell activation, which

in turn causes activation of coagulation and thrombus formation. The circulation of free thrombin, which cannot not be controlled by natural anticoagulants, can lead to platelet activation and cause thrombosis. Severe inflammatory status is characterized by an increase in CRP and D-dimer, which indicates a disorder of the coagulation cascade that plays a role in the hypercoagulability status of COVID-19 patients.<sup>9</sup> Hypoxia also triggers the infiltration of inflammatory cells and the release of cytokines, which in turn contribute to tissue ischemia. Inflammation plays an important role in the development and prognosis of cerebrovascular disease. Patients with severe infections typically exhibit higher plasma cytokine levels, such as IL-2, IL-7, IL-10, GSCF, IP10, MCP1, and MIP1A. The inflammatory process also promotes atherosclerosis and affects plaque stability.<sup>3</sup>

Coronavirus disease 2019 infection can also cause hemorrhagic stroke, particularly in patients older than 60 yo. Older individuals often present with more severe systemic symptoms, such as thrombocytopenia, and in addition to increased levels of D-dimer, would increase the risk hemorrhagic stroke. Furthermore, cytokine storms and predominant sympathetic activation in COVID-19 also increase the risk of aneurysms and vascular rupture, which may turn into hemorrhagic stroke.<sup>3,15</sup>

The concept of protected code stroke (PCS) has been introduced to provide effective care for stroke patients during the COVID-19 pandemic.<sup>16</sup> The PCS recommends that paramedics screen for COVID-19 infection in all patients with stroke-like symptoms before taking them to hospital. All healthcare professional exposed to patients are required to use personal protective equipment (PPE), including full-sleeve gown, surgical mask, head covering, face shield, and gloves. External transfer should be minimized, and patients who required

to be transferred should be screened for infection.<sup>16</sup>

The COVID-19 pandemic also posed some difficulties in examining patients. In many centers, although exhibiting signs and symptoms of stroke, patients could not receive proper treatment due to limitations in radiological examination. Fortunately, in our facility, a separate CT-scan for COVID-19 is available; thus, no patients are neglected from treatment.

Early anticoagulant administration for COVID-19 infection is recommended by Chinese authorities to improve clinical outcome, but no specific inclusion or exclusion criteria have been established. Low-molecular-weight heparin (LMWH) is widely used to prevent disseminated intravascular coagulation (DIC) and venous thromboembolism (VTE). LMWH also has anti-inflammatory effects, which may benefit COVID-19 patients. Complication of LMWH administration, such as bleeding, are rare and usually mild when they occur. Expert consensus suggests that LMWH prophylaxis should be administered upon admission and continued for 7-14 days after discharge. For severe COVID-19 patients with coagulopathy, unfractionated heparin or LMWH is recommended to reduce coagulation substrate depletion. In critically ill patients, LMWH or unfraction heparin (UFH) is preferable to oral anticoagulants due to their shorter half-life.<sup>4,17</sup> In a series of five cases of large vessel stroke in COVID-19 patients, antiplatelets were initially administered, but later switched to anticoagulants. Anticoagulant prophylaxis with LMWH is recommended for stroke cases with COVID-19 infection. Early anticoagulation with LMWH may be useful in reducing the risk of thromboembolism in COVID-19-associated stroke patients, while considering the risk of intracranial hemorrhage or the transformation of infarct stroke into hemorrhagic.<sup>18</sup>

In the Indonesian guideline of COVID-19, prophylaxis with LMWH

or UFH is recommended for moderate and severe COVID-19.<sup>19</sup> None of our cases received any anticoagulant prophylaxis, as they arrived at our facility after developing thromboembolic complication.

The SARS-CoV-2 specifically binds to the ACE2 receptor, which may increase the risk of intracranial hemorrhage in patients with hypertension. Critically ill COVID-19 patients also tend to have severe thrombocytopenia, another risk factor for cerebral hemorrhage. Therefore, antihypertension therapy is essential for COVID-19 patient with hypertension comorbidity. ACE inhibitors or angiotensin receptor blockers (ARBs) are not recommended as antihypertensive drugs. Other classes of antihypertensive medications, such as calcium channel blockers (CCBs), diuretics, and others, should be considered for treating hypertension in COVID-19 infection.<sup>20</sup>

## CONCLUSION

In this case series, two cases of COVID-19 with stroke as thromboembolic complication of the infection was reported. One patient also had myocardial injury, while another had DVT. Anticoagulants play an important role in preventing those events, but since stroke in COVID-19 patients carries an increased risk of bleeding, these medications should be administered with more caution.

## ACKNOWLEDGEMENT

There is no financial support to report.

## REFERENCES

1. Wu Y, Xu X, Chen Z, Duan J, Hashimoto K, Yang L, *et al.* Nervous system involvement after infection with COVID-19 and other coronaviruses. *Brain Behav Immun* 2020; 87:18-22.

- <https://doi.org/10.1016/j.bbi.2020.03.031>
2. Connors JM, Levy JH. COVID-19 and its implications for thrombosis and anticoagulation. *Blood* 2020; 135(23):2033-40.  
<https://doi.org/10.1182/blood.2020006000>
  3. Zhai P, Ding Y, Li Y. The impact of COVID-19 on ischemic stroke: a case report. *Diagn Pathol* 2020; 15(1):78.  
<https://doi.org/10.1186/s13000-020-00994-0>
  4. Tang N, Bai H, Chen X, Gong J, Li D, Sun Z. Anticoagulant treatment is associated with decreased mortality in severe coronavirus disease 2019 patients with coagulopathy. *J Thromb Haemost* 2020; 18(5):1094-9.  
<https://doi.org/10.1111/jth.14817>
  5. Morassi M, Bagatto D, Cobelli M, D'Agostini S, Gigli GL, Bnà C, *et al*. Stroke in patients with SARS-CoV-2 infection: Case series. *J Neurol* 2020; 267(8):2185-2192.  
<https://doi.org/10.1007/s00415-020-09885-2>
  6. Ortega-Paz L, Capodanno D, Montalescot G, Angiolillo DJ. Coronavirus disease 2019-associated thrombosis and coagulopathy: Review of the pathophysiological characteristics and implications for antithrombotic management. *J Am Heart Assoc* 2021; 10(3):e019650.  
<https://doi.org/10.1161/JAHA.120.019650>
  7. Needham EJ, Chou SHY, Coles AJ, Menon DK. Neurological implications of COVID-19 infections. *Neurocrit Care* 2020; 32(3):667-71.  
<https://doi.org/10.1007/s12028-020-00978-4>
  8. Rahman A, Tabassum T, Araf Y, Al Nahid A, Ullah MA, Hosen MJ. Silent hypoxia in COVID-19: pathomechanism and possible management strategy. *Mol Biol Rep* 2021; 48(4):3863-9.  
<https://doi.org/10.1007/s11033-021-06358-1>
  9. McGonagle D, Sharif K, O'Regan A, Bridgewood C. The role of cytokines including interleukin-6 in COVID-19 induced pneumonia and macrophage activation syndrome-like disease. *Autoimmun Rev* 2020; 19(6):102537.  
<https://doi.org/10.1016/j.autrev.2020.102537>
  10. Zhou F, Yu T, Du R, Fan G, Liu Y, Liu Z, *et al*. Clinical course and risk factors for mortality of adult inpatients with COVID-19 in Wuhan, China: a retrospective cohort study. *Lancet* 2020; 395(10229):1054-62.  
[https://doi.org/10.1016/S0140-6736\(20\)30566-3](https://doi.org/10.1016/S0140-6736(20)30566-3)
  11. Beyrouti R, Adams ME, Benjamin L, Cohen H, Farmer SF, Goh YY, *et al*. Characteristics of ischaemic stroke associated with COVID-19. *J Neurol Neurosurg Psychiatry* 2019; 92(7):889-91.  
<https://doi.org/10.1136/jnnp-2020-323586>
  12. Salahuddin H, Castonguay AC, Zaidi SF, Burgess R, Jadhav AP, Jumaa MA. Interventional stroke care in the era of COVID-19. *Front Neurol* 2020; 11:468.  
<https://doi.org/10.3389/fneur.2020.00468>
  13. Brüggemann R, Gietema H, Jallah B, Cate H ten, Stehouwer C, Spaetgens B. Arterial and venous thromboembolic disease in a patient with COVID-19: a case report. *Thromb Res* 2020; 191:153-5.  
<https://doi.org/10.1016/j.thromres.2020.04.046>
  14. Nagele PM, Haubner B, Tanner FC, Ruschitzka F, Flammer AJ. Endothelial dysfunction in COVID-19: current findings and therapeutic implications. *Atherosclerosis* 2020; 314:58-62.  
<https://doi.org/10.1016/j.atherosclerosis.2020.10.014>
  15. Al Saiegh F, Ghosh R, Leibold A, Avery MB, Schmidt RF, Theofanis T, *et al*. Status of SARS-CoV-2 in cerebrospinal fluid of patients with COVID-19 and stroke. *J Neurol Neurosurg Psychiatry* 2020;



- 91(8):846-8.  
<https://doi.org/10.1136/jnnp-2020-323522>
16. Khosravani H, Rajendram P, Notario L, Chapman MG, Menon BK. Protected code stroke: hyperacute stroke management during the coronavirus disease 2019 (COVID-19) pandemic. *Stroke* 2020; 51(6):1891-5.  
<https://doi.org/10.1161/STROKEAHA.120.029838>
  17. Hughes C, Nichols T, Pike M, Subbe C, Elghenzai S. Cerebral venous sinus thrombosis as a presentation of COVID-19. *Eur J Case Reports Intern Med* 2020; 7(5):001691.  
[https://doi.org/10.12890/2020\\_001691](https://doi.org/10.12890/2020_001691)
  18. Oxley TJ, Mocco J, Majidi S, Kellner CP, Shoirah H, Singh IP, et al. Large-vessel stroke as a presenting feature of Covid-19 in the young. *N Engl J Med* 2020; 382(20):e60.  
<https://doi.org/10.1056/NEJMc210078719>
  19. Burhan E, Susanto AD, Nasution SA, Eka G, Pitoyo ceva W, Susilo A, et al. Pedoman tatalaksana COVID-19 edisi 4. Jakarta: PDPI, PERKI, PAPDI, PERDATIN, IDAI, 2022.
  20. Jin H, Hong C, Chen S, Zhou Y, Wang Y, Mao L, et al. Consensus for prevention and management of coronavirus disease 2019 (COVID-19) for neurologists. *Stroke Vasc Neurol* 2020; 5(2):146-51.  
<https://doi.org/10.1136/svn-2020-000382>