



JMedSci

## A rare case of *Salmonella* sp septic arthritis in a patient with systematic lupus erythematosus (SLE)

Mario Steffanus<sup>1</sup>, Cindy Yusuf<sup>1</sup>, Jessica Novia Hadiyanto<sup>2\*</sup>

<sup>1</sup>Department of Internal Medicine, School of Medicine and Health Sciences Atma Jaya, Jakarta, Indonesia, <sup>2</sup>Department of Internal Medicine, Faculty of Medicine, Dr. Kariadi Hospital, Diponegoro University, Semarang, Central Java, Indonesia

### ABSTRACT

Submitted: 2021-08-19  
Accepted : 2021-10-24

Septic arthritis is considered as a medical emergency which can lead to significant morbidity and cause substantial mortality, especially if the diagnosis is delayed. Prolonged use of immunosuppressive and cytotoxic medications as therapy for systemic lupus erythematosus (SLE) causing patient susceptible to secondary infection. However, septic arthritis due to *Salmonella* sp. is very rare, makes this is an important extraintestinal manifestation especially in immunosuppressed patients. We presented a case of 25 y.o. female diagnosed with SLE 3 m.o. earlier presented with fever and arthritis on her left genu for 1 wk duration. Genu ultrasonography showed synovitis genu sinistra with fluid volume of 1-2 cc on recessus lateral genu sinistra. The patient was further analysis on her synovial fluid was conducted, the gram stained smear of the fluid showed >25 leucocytes, low power field, and *Salmonella* sp. was isolated from her synovial fluid analysis. The patient was given intravenous ciprofloxacin and discharged home well. Septic arthritis should always be considered in any patients on long-term immunosuppression state who present with acutely swollen joints. It considered as an important medical emergency with high mortality and morbidity. Hence, prompt recognition, joint aspiration with administration of systemic antibiotics and appropriate surgical intervention plays a pivotal role to minimize morbidity and mortality.

### ABTRAK

Artritis septik merupakan suatu kegawatdaruratan medis yang dapat menyebabkan morbiditas dan mortalitas yang signifikan terutama bila diagnosis terlambat ditegakkan. Penggunaan terapi immunosupresif dan sitotoksik dalam jangka waktu panjang sebagai terapi lupus eritematosus sistemik (LES) dapat menyebabkan pasien lebih rentan mengalami infeksi sekunder. Namun, artritis septik yang disebabkan oleh *Salmonella* sp. sangatlah langka. Hal ini menjadi manifestasi ekstraintestinal yang penting terutama pada pasien dengan imunokompromis. Kami melaporkan seorang pasien perempuan berusia 25 tahun yang terdiagnosis dengan LES 3 bulan sebelumnya. Pasien mengalami demam dan artritis pada genu kiri selama 1 minggu. Ultrasonografi genu menunjukkan adanya sinovitis pada genu sinistra dengan volume cairan 1-2 mL pada recessus lateral genu sinistra. Selanjutnya, dilakukan analisis cairan sinovial dimana pewarnaan Gram menunjukkan adanya >25 leukosit pada perbesaran rendah dan ditemukan *Salmonella* sp. pada cairan sinovial. Pasien mendapatkan terapi siprofloksasin intravena. Pasien akhirnya dapat keluar dari rumah sakit setelah dinyatakan sembuh. Adanya artritis septik harus selalu dipertimbangkan pada pasien dengan terapi immunosupresif jangka panjang yang mengalami pembengkakan sendi akut. Artritis septik dianggap sebagai kegawatdaruratan medis penting dengan mortalitas dan morbiditas yang tinggi. Oleh karena itu, diagnosis dini, aspirasi sendi, pemberian antibiotik sistemik, dan intervensi pembedahan yang tepat memegang peranan penting untuk menurunkan morbiditas dan mortalitas pada kasus artritis septik.

### Keywords:

septic arthritis;  
systemic lupus  
erythematosus;  
*Salmonella*;  
case report;  
immunosuppression

\*corresponding author: [odiliajessicanovia@gmail.com](mailto:odiliajessicanovia@gmail.com)

## INTRODUCTION

Septic arthritis is a rapid and progressive infection caused by invasion of bacteria, virus or fungus into the synovial joint.<sup>1</sup> It is known to be the most threatening of the multiple causes of acute joint pain.<sup>2</sup> The incidence of septic arthritis is between 2 to 6 cases per 100,000 people but varies based on the presence of risk factors.<sup>3</sup> It is considered as an important medical emergency which can be associated with significant morbidity and can cause substantial mortality.<sup>2</sup>

Systemic lupus erythematosus (SLE) is regarded as the most common underlying disease due to avascular necrosis.<sup>4</sup> The prevalence of SLE varies between 4 and 27%.<sup>5</sup> Prolonged use of immunosuppressive and cytotoxic medications as therapy for SLE causing patient susceptible to secondary infection.

In all age and risk groups, the most frequent causative organisms identified are *Staphylococcus aureus* followed by other gram positive bacteria, including *Streptococci*.<sup>6</sup> *Salmonella pyogenic* infection on joints only occurs in less than 1% of cases, that makes this is a rare yet important extraintestinal manifestation.<sup>7</sup>

Septic arthritis caused by *Salmonella* is frequently unidentified in early phase of the disease due to its unspecific symptoms and signs. A delay in diagnosis or inadequate treatment is not infrequent, which can lead to irreversible joint destruction and increasing mortality.<sup>2</sup> This case report indicates the importance of prompt recognition and timely diagnosis through synovial fluid aspiration of relevant joints, the choice of suitable antibiotics,

and appropriate intervention to restrain permanent disability particularly in immunosuppressed patient.

## CASE

A 25 y.o. woman was admitted via the emergency room presented with fever 1 d prior to admission and worsening pain on her left knee for a wk duration. The pain was non radiating, severe in intensity with a scale 8 out of 10 and aggravated by movement at the knee. The patient did not have any history of trauma, prior surgery, and there were no accompanying symptoms or pain and swelling in any other joint of the body. The patient was diagnosed with SLE 3 m.o. before admission, characterized by malar rash, oral ulcer, proteinuria, and arthritis. She was maintained with methylprednisolone 16 mg q.d., mychophenolate mofetil 500 mg b.i.d. and had not reported any symptoms during the previous months.

Upon admission, she was compositis, with a blood pressure 110/60 mmHg, cardiac rate 110 times/min, respiratory rate 22 times/min, and temperature of 37.8 °C. The physical examination on her left genu showed a swollen, erythematous knee, which was warmth, oedema and tender on palpation with decreased range of motion of the knee flexion and extension due to pain. The remainder of the physical examination was within normal limits. Laboratory examination showed hemoglobin levels 12.4 g/dL, leukocytes  $15.26 \times 10^6/L$ . Renal function tests, electrolytes and liver enzymes were normal.

A consideration of secondary septic arthritis was made as she was in immunosuppressed state. Before

the results of the synovial fluid culture and sensitivity test, the patient was started empirically with intravenous ceftriaxone 2 g q.d., daily medications were continued. Afterwards, she underwent further examination, joint aspiration was performed. Her synovial fluid analysis revealed yellow color, cloudy, with 80,000 erythrocyte/mm<sup>3</sup>, 58,750 leucocytes/mm<sup>3</sup> and negative for monosodium urate monohydrate. The

Gram stained smear of the fluid showed >25 leucocytes, low power field, there was no Gram negative diplococcus bacteria aspirated from her synovial fluid, and the culture results found *Salmonella* sp. growth which was sensitive to ceftazidime and ciprofloxacin.

Ultrasonography was performed and it showed synovitis genu sinistra with fluid volume of 1-2 cc on recessus lateral genu sinistra (FIGURE 1).

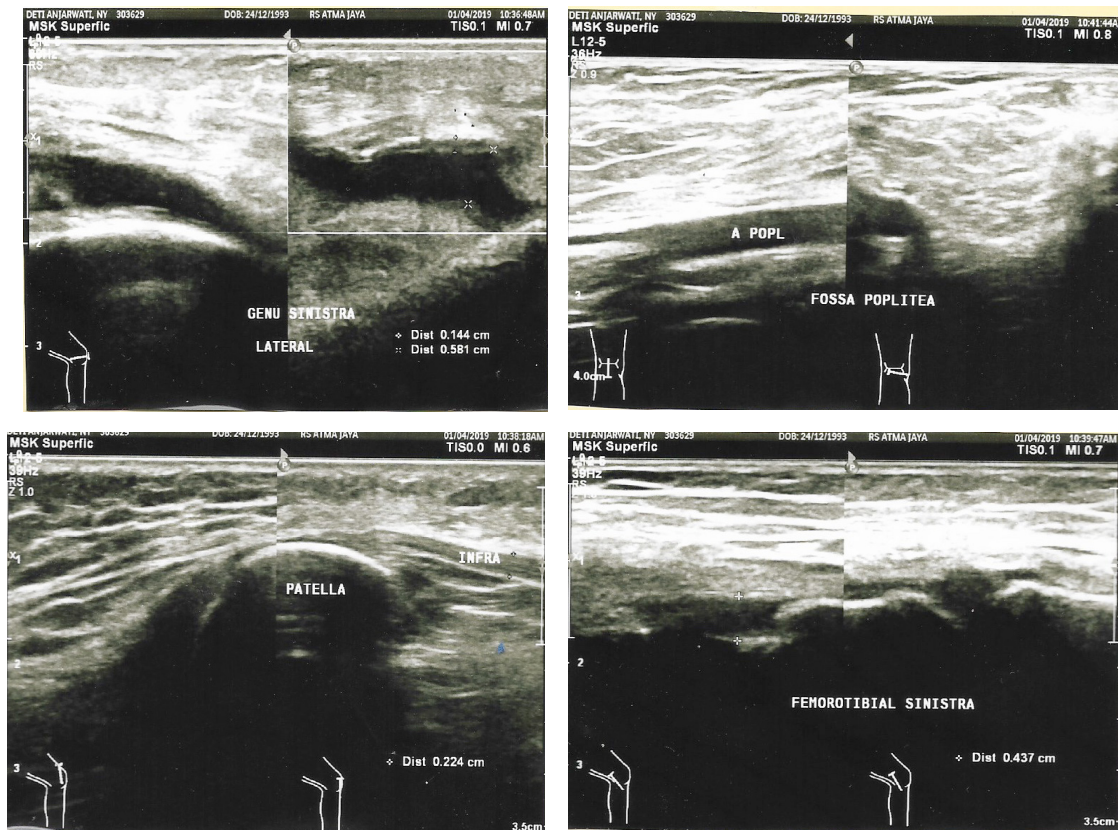


FIGURE 1. Ultrasound of the genu sinistra which showed synovitis with fluid volume of 1-2 cc on recessus lateral genu sinistra

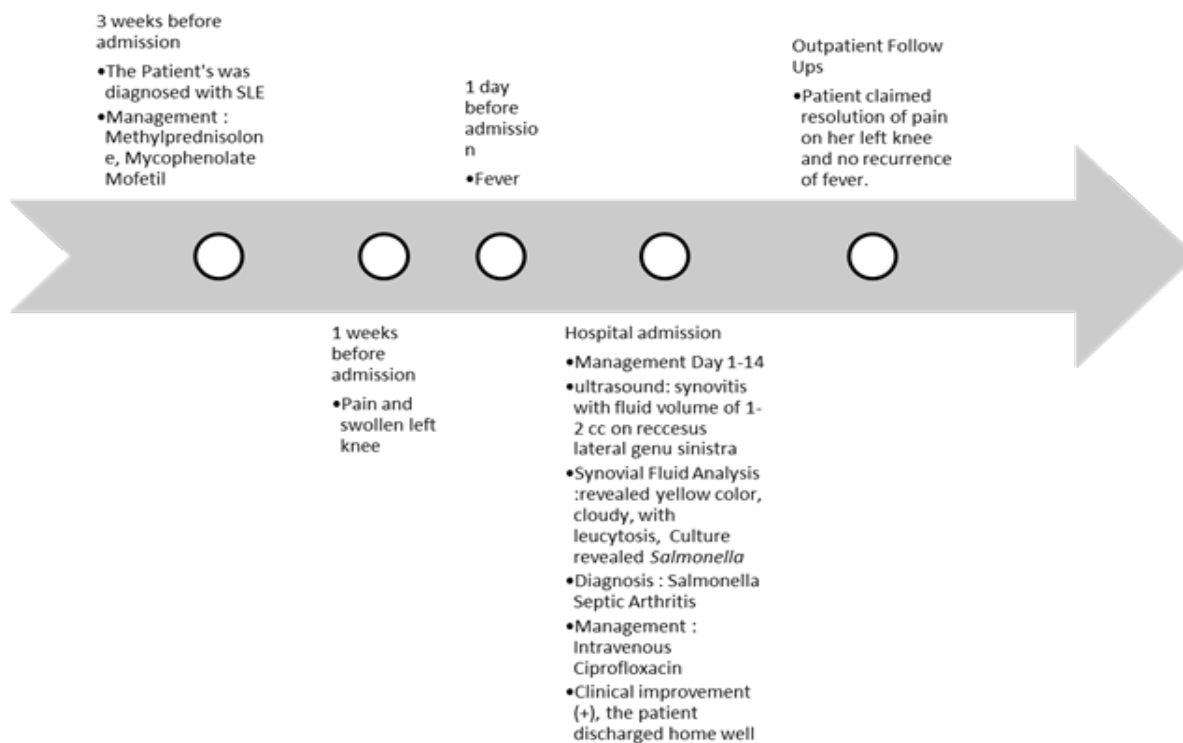


FIGURE 2. Timeline of case

Based on the findings obtained, all results established the diagnosis of *Salmonella* related septic arthritis. On account of the culture results, her antibiotic changed to intravenous ceftazidime and ciprofloxacin for 2 wk before switching to oral cefixime and ciprofloxacin to be continued for 2 wk. Duration of treatment in studies ranged from 4 to 6 wk, split into 1-2 wk of intravenous antibiotics, depending on patient's response, and a further 3-4 wk of oral antibiotics.<sup>7</sup> She was monitored closely; surveillance aspirations of knees had negative microbiology cultures. Clinically, gradual improvement of patient's arthritis was noted and was then discharged home well. Her outpatient follow-up examinations for up to 6 m.o. were uneventful with

no complaints of joint pain and no recurrence of febrile episodes. A case timeline of the patient's history, clinical manifestation, management, and follow up are summarized in FIGURE 2.

## DISCUSSION

Infection can have fatal consequences and accounts for 25% mortality in patients with SLE.<sup>8</sup> In patients treated with immunosuppressant medication, pulmonary, opportunistic and septic arthritis are the most common infections.<sup>9</sup> Septic arthritis is known to be the most threatening of the multiple causes of acute joint pain, and can be associated with significant morbidity, including permanent joint dysfunction.<sup>4,10</sup> It has long been viewed as an orthopedic

emergency as it can lead to significant morbidity and even mortality.<sup>10</sup> In adults of all age groups with septic arthritis, *S. aureus* is the most common causative organism, followed by group A *Streptococcus*, *Haemophilus influenzae* type b, *Streptococcus pneumoniae*, and *Brucella melitensis*<sup>1,2,10</sup> *Salmonella* sp. (including typhoidal and non-typhoidal strains) arthritis is atypical and accounts for only 1% of all cases.<sup>1,7,8,11,12</sup> The most common *Salmonella* sp. serotypes isolated from these SLE patients were type B and D, and *S. enteritidis* was the most common pathogen causing septic arthritis in younger SLE patients.<sup>4,14</sup>

*Salmonella* consists of a large heterogeneous group of gram negative bacilli, this intracellular organism may act as a carrier and causes widespread infection in the immunosuppressed state.<sup>8,11,14</sup> It can be easily eradicated in healthy individuals, but it causes widespread infections in immunosuppressed patients, infection can spread through hematogen and present as focal lesions in any organ with or without suppuration and associated with gastrointestinal infection, but immunosuppression leads to an increased risk of bacteremia, endovascular infection, soft-tissue abscesses, and bone and joint involvement.<sup>8,11,15</sup>

Several authors have addressed predisposing factors that associated with *Salmonella*-related septic arthritis, these factors included: connective tissue diseases (15.5%), HIV (18.6-20%), malignancy (23.6-36.4%), diabetes mellitus (29.5%), immunosuppressive conditions, chronic kidney diseases, atherosclerosis and hypertension (27.9-69.1%), age > 65 yr, gastrectomy, chronic lung diseases, rheumatoid arthritis, amyloidosis,

immunosuppressive therapy (steroids, cytotoxic chemotherapy), leukemia and lymphoma, and thalassemia.<sup>10,12,16,20</sup> SLE is regarded as the most common underlying disease in patients with *Salmonella* bacteremia.<sup>7,12</sup> Self-limited gastroenteritis and bacteremia, with or without extra-intestinal focal infections (EFIs), are common clinical presentations of nontyphoidal salmonellosis.<sup>5,18</sup> *Salmonella typhi* septic arthritis occurs less frequently, tends to affect adolescents and young adults and has predilection for the left sacroiliac joint.<sup>4,7</sup> The etiopathogenesis of AVN in SLE can be caused by multiple factors, such as high-dose or long-duration steroid therapy, immunosuppressant therapy, positivity for antiphospholipid antibody, lupus nephritis, neuropsychiatric lupus, and cushingoid status.<sup>5</sup> High susceptibility to *Salmonella* infection in SLE patients may be due to hypocomplementemia, a phagocytosis defect, defective turnout necrosis factor production, increased haemolysis, a cellular immune defect, immunosuppressant drugs, incomplete antibiotic use and glomerulonephritis.<sup>8</sup>

*Salmonella* septic arthritis developed within 1-53 m.o. after SLE diagnosis. The reactivation of latent infection and new infection may both be possible routes. A common predisposing articular factor for *Salmonella* septic arthritis is avascular necrosis (AVN) and osteonecrosis (ON).<sup>8,11,15</sup> The complications of AVN, cellular immune defect by steroid use and alcoholic liver disease may induce a disturbance of the osseous arterioles and even microvascular tamponade, which then becomes a local factor for *Salmonella* infection and provided a favorable environment for persistent bone infection following an episode of bacteraemia.<sup>9,11</sup>

Smith *et al.*<sup>19</sup> reported that enzymatic destruction begins by the 8 h after the inoculation. By the 48<sup>th</sup> h, 40% of the glycosaminoglycan is lost, and collagen breakdown occurs in a period of few days in septic arthritis.<sup>19</sup> Nierenberg *et al.*<sup>2</sup> previously reported a case of young woman diagnosed with SLE, end stage renal disease on hemodialysis (ESRD), and chronic joint pain that progressed into rapid septic shock within hours. This proves that prompt and timely diagnosis of the septic joint is very important, but the time course is usually considered to be within the day, and the notion of the “golden hour” for septic shock is not often considered.<sup>2</sup> Septic arthritis should always be treated as a potential septic emergency and diagnosis and institution of definitive therapy needs to be started in a time frame corresponding to sepsis, especially in the immunocompromised patient.<sup>9</sup>

The gold standard of treatment is joint debridement and antibiotic therapy according to the culture results. *Salmonella* is mostly sensitive to fluoroquinolones and third generation cephalosporins.<sup>1-10,12,19,20</sup> Duration of treatment in studies ranged from 4 to 6 wk, split into 1-2 wk of intravenous antibiotics, depending on patient's response, and a further 3-4 wk of oral antibiotics. Early initiation of effective antibiotics has been reported to result in good clinical response.<sup>7-9</sup>

In our patient, the presence of immunosuppressed state act as predispose factor for *Salmonella* septic arthritis infection due to avascular necrosis or osteonecrosis. We believe she might have had an earlier subclinical gastrointestinal infection, and it presents as a result

of hematogenous spread. Appropriate antibiotic therapy and joint aspiration should be administered immediately. In most septic arthritis, *Salmonella* is not suspected as common etiology and the diagnosis is established following its isolation. Therefore, empiric therapy of septic arthritis should be targeted against *S. aureus* and *Streptococci*, in conjunction with *Salmonella* should taken into consideration particularly in immunocompromised patient.<sup>10</sup> Definitive therapy for septic arthritis is based on the identification and antibiotic susceptibility of the bacteria isolated in the synovial fluid culture.<sup>20</sup>

## CONCLUSION

Septic arthritis should always be considered in any patients with immunosuppression state who present with acutely swollen joints. *Salmonella* is the most common pathogen particularly in younger SLE patients. In our patient, the SLE and use of glucocorticoids would have created an immunocompromised state which become major predisposition for *Salmonella* infection. Prompt recognition, joint aspiration and microbiology should always be obtained with prolonged administration of systemic antibiotics and appropriate surgical intervention play a pivotal role in successful treatment.

## ACKNOWLEDGEMENTS

No conflict of interest is declare.

## REFERENCES

1. Kurniawan A, Sitorus IP, Loho T, Hutami WD. A rare case of septic

- arthritis of the knee caused by *Salmonella typhi* with preexisting typhoid fever in a healthy, immunocompetent child – a case report. *Int J Surg Case Rep* 2021; 78:76-80.  
<https://doi.org/10.1016/j.ijscr.2020.12.003>
2. Nierenberg RJ, Berliner B, Seidenstein A. Infectious arthritis leading to rapid septic shock in a patient with SLE, leukopenia, and end stage renal disease: a case presentation and cautionary notes. *Ann Clin Case Rep* 2020; 5(1):1779(1-5).
  3. Hassan AS, Rao A, Manadan AM, Block JA. Peripheral bacterial septic arthritis: review of diagnosis and management. *J Clin Rheumatol* 2017; 23(8):435-42.  
<https://doi.org/10.1097/RHU.0000000000000588>
  4. Huang CF, Chen PL, Liu MF, Lee CC, Lee NY, Chang CM, et al. Nontyphoidal *Salmonella* bacteremia in patients with connective tissue diseases. *J Microbiol Immunol Infect* 2012; 45(5):350-5.  
<https://doi.org/10.1016/j.jmii.2011.12.013>
  5. Kunyakhm W, Foocharoen C, Mahakkanukrauh A, Suwannaroj S, Nanagara R. Prevalence and risk factor for symptomatic avascular necrosis development in Thai systemic lupus erythematosus patients. *Asian Pac J Allergy Immunol* 2012; 30(2):152-7.
  6. Mathews CJ, Weston VC, Jones A, Field M, Coakley G. Bacterial septic arthritis in adults. *Lancet* 2010; 375(9717):846-55.  
[https://doi.org/10.1016/S0140-6736\(09\)61595-6](https://doi.org/10.1016/S0140-6736(09)61595-6)
  7. Umar AA, Ahmed MS, Tuko MT, Usman BO. *Salmonella typhi* septic sacroiliitis in a young Nigerian. *Sub-Saharan Afric J Med* 2016; 3(3):166-9.  
<https://doi.org/10.4103/2384-5147.190863>
  8. Kim SS, Perino G, Boettner F, Miller A, Goodman S. *Salmonella* septic arthritis of the knees in a patient with systemic lupus erythematosus. *Lupus* 2013; 22(7):740-3.  
<https://doi.org/10.1177/0961203313491022>
  9. Salar O, Baker B, Kurien T, Taylor A, Moran C. Septic arthritis in the era of immunosuppressive treatments. *Ann R Coll Surg Engl* 2014; 96(2):11-2.  
<https://doi.org/10.1308/003588414X13814021678196>
  10. Wang DA, Tambyah PA. Septic arthritis in immunocompetent and immunosuppressed hosts. *Best Pract Res Clin Rheumatol* 2015; 29(2):275-89.  
<https://doi.org/10.1016/j.berh.2015.05.008>
  11. Shanthi M, Sekar U, Sridharan KS. Septic arthritis of hip caused by *Salmonella typhi*: a case report. *Case Rep Infect Dis* 2012; 2012:464527.  
<https://doi.org/10.1155/2012/464527>
  12. El-Herte RI, Haidar RK, Uthman IW, Kanj SS. *Salmonella enteritidis* bacteremia with septic arthritis of the sacroiliac joint in a patient with systemic lupus erythematosus: case report and review of the literature. *J Med Liban* 2011; 59(4):235-7.
  13. Gupta P, Kaistha N, Omar BJ, Gupta P, Singh V, Mohanty A. *Salmonella typhi*: a cause of septic arthritis knee: a rare entity. *Int J Biomed Res* 2017; 8(4):242-4.  
<https://doi.org/10.7439/ijbr.v8i4.4084>
  14. Wu CJ, Huang CC, Weng SF, Chen PJ, Hsu CC, Wang JJ, et al. Septic arthritis significantly increased the long-term mortality in geriatric patients. *BMC Geriatr* 2017; 17(1):178.  
<https://doi.org/10.1186/s12877-017-0561-x>
  15. Ribeiro DS, Neto CA, D'Almeida F, Galvão VL, Santiago MB. Imaging

- findings of musculoskeletal disorders associated with systemic lupus erythematosus. *Radiologia Brasileira* 2011; 44(1):52-8.  
<https://doi.org/10.1590/S0100-39842011000100013>
16. Hohmann EL. Nontyphoidal Salmonellosis. *Clin Infect Dis* 2001; 32(2):263-9.  
<https://doi.org/10.1086/318457>
  17. Sukswai P, Kovitvanitcha D, Thumkunanon V, Chotpitayasunondh T, Sangtawesin V, Jeerathanyasakun Y. Acute hematogenous osteomyelitis and septic arthritis in children: clinical characteristics and outcomes study. *J Med Assoc Thai* 2011; 94 Suppl 3:S209-S216.
  18. Munigangaiah S, Khan H, Fleming P, Dolan MA. Septic Arthritis of the adult ankle joint secondary to *Salmonella enteritidis*: a case report. *J Foot Ankle Surg* 2011; 50(5):593-4.  
<https://doi.org/10.1053/j.jfas.2011.04.039>
  19. Uygur E, Reddy K, Özkan FÜ, Söylemez S, Aydın Ö, Şenol S. *Salmonella enteritis* septic arthritis: a report of two cases. *Case Rep Infect Dis* 2013; 2013:642805.  
<https://doi.org/10.1155/2013/642805>
  20. Mansour E, El-Masri F. Bilateral *Salmonella* septic arthritis of the hip in a patient with Crohn disease: a case report. *JBJS Case Connect* 2016; 6(4):e91.  
<https://doi.org/10.2106/JBJS.CC.16.00045>