



## The eyelid tumor in Yogyakarta, Indonesia

**Agus Supartoto\***, Annisa Nurina Ayuningtyas, Banu Aji Dibyasakti, Purjanto Tepo Utomo, Datu Respatika, Muhammad Bayu Sasongko

Reconstruction, Oculoplasty, Oncology Subdivision, Department of Ophthalmology, Faculty of Medicine, Public Health and Nursing, Universitas Gadjah Mada / Dr. Sardjito General Hospital, Yogyakarta

### ABSTRACT

Submitted: 2019-04-01  
Accepted : 2019-06-18

Many types of eyelid tumors may easily be diagnosed from a clinical point of view. However only a small number of large studies exist exploring the frequency of eyelid lesions from different regions. According to the epidemiology of various eyelid lesions happened in Yogyakarta Special Region, this study was aimed to investigate the prevalence of eyelid tumors in Yogyakarta Special Region. A total of 94 patients were enrolled in a descriptive study. The data were taken retrospectively from the medical record. All patients were diagnosed with eyelid tumors from January 2014 until December 2017 by histopathological examination. Among the subjects, 56 (59.6%) were male and 38 (40.4%) were female. There was no difference found in laterality (OD 46% vs OS 50%). Sebaceous carcinoma was found in 15 (16%) patients, followed by squamous cell carcinoma (SCC) 13 (13.8%), basal cell carcinoma (BCC) 11 (11.7%), epidermoid cyst 7 (7.4%), non-Hodgkin lymphoma 7 (7.4%), and others. We also found that 11 (11.7%) of patients showed an inflammation appearance only. The therapy was varied from extirpation and biopsy (39.4%), wide excision (27.7%), excision and biopsy (18.1%), exenteration (10.6%), and also anterior and lateral orbitotomy (2.1%) for each procedure. The eyelid tumor was found equally in the right and the left eye. Sebaceous carcinoma followed by SCC and BCC were the most common eyelid tumor found in this study. A further study is needed to determine the risk factor of each tumor.

### ABSTRAK

Banyak jenis tumor kelopak mata dapat dengan mudah didiagnosis dari sudut pandang klinis, hanya sedikit penelitian yang mengeksplorasi frekuensi lesi kelopak mata dari berbagai tempat. Berdasarkan kejadian epidemiologi mengenai lesi kelopak mata di Daerah Istimewa Yogyakarta, penelitian ini bertujuan untuk menyelidiki prevalensi tumor kelopak mata di Daerah Istimewa Yogyakarta. Sebanyak 94 pasien terdaftar dalam penelitian deskriptif. Data diambil secara retrospektif dari rekam medis. Semua pasien didiagnosis dengan tumor kelopak mata dari Januari 2014 hingga Desember 2017 dengan pemeriksaan histopatologis. Di antara subyek, 56 (59,6%) adalah laki-laki dan 38 (40,4%) adalah perempuan. Tidak ada perbedaan yang ditemukan dalam lateralitas (OD 46% vs OS 50%). Karsinoma sebacea ditemukan pada 15 (16%) pasien, diikuti oleh karsinoma sel skuamosa (SCC) 13 (13,8%), karsinoma sel basal (BCC) 11 (11,7%), kista epidermoid 7 (7,4%), limfoma non-Hodgkin 7 (7,4%), dan lainnya. Kami juga menemukan bahwa 11 (11,7%) pasien menunjukkan penampilan inflamasi saja. Terapi ini bervariasi dari ekstirpasi dan biopsi (39,4%), eksisi luas (27,7%), eksisi dan biopsi (18,1%), exenterasi (10,6%), dan juga orbitotomi anterior dan lateral (2,1%) untuk setiap prosedur. Tumor kelopak mata ditemukan sama di mata kanan dan kiri. Karsinoma sebaceous diikuti oleh SCC dan BCC adalah tumor kelopak mata yang paling umum ditemukan dalam penelitian ini. Diperlukan penelitian lebih lanjut untuk menentukan faktor risiko masing-masing tumor.

### Keywords:

eyelid tumor  
sebaceous carcinoma  
squamous cell carcinoma  
basal cell carcinoma

## **INTRODUCTION**

Eyelid tumors are commonly diagnosed neoplasms in routine ophthalmology practices.<sup>1</sup> Benign and malignant tumors can arise from each of the eyelid layers. Some malignant tumors may mimic benign neoplastic and, inflammatory conditions and cause late diagnosis.<sup>2</sup> A wide variety of benign and malignant tumors can originate because of the existence of many different tissue types in the eyelids.<sup>3</sup> Different cell types of epidermis, Meibomian, Zeiss, Moll, Wolfring and Krause glands, eyelash follicles may all cause eyelid tumors. Eyelid lesions represent 15% of face tumors and 5-10% from all cutaneous tumors.<sup>3,4</sup> The highest incidence of eyelids tumor was reported after age of 60, and most of tumors were situated in the lower eyelid and internal canthus.<sup>5,6</sup>

The global distribution of eyelid swellings vary remarkably and their incidence appear to be increasing. Eyelid lesions can be non-neoplastic or neoplastic. Most of them are benign in nature; but some are malignant and are quite similar to skin cancers.<sup>7</sup> Among skin cancers, 90% were arise in the head and neck region and 10% of them are located at eyelid level. Basal cell carcinoma is the most common malignant eyelid tumor in western countries, whereas in Asia, the frequency of sebaceous gland carcinoma and squamous cell carcinoma are relatively high when compared to other type of tumor.<sup>8</sup> The most prevalent benign lesions in most studies were dermoid cysts, nevi, epidermal cysts and papilloma.<sup>9-11</sup>

Although many types of eyelid tumors may easily be diagnosed from a clinical point of view, some should be diagnosed with pathological specimens. Only a small number of large studies exist exploring the frequency of eyelid lesions from different sites of the world.<sup>12</sup> According to the epidemiology of various eyelid lesions in our location we can improve the availability of appropriate treatment strategies in our hospital. To date, there is no data about eyelid tumor in Yogyakarta Special Region. This study was aimed to investigate the prevalence of eyelid tumor in one health center as tertiary referral hospital in Yogyakarta Special Region in Indonesia.

## **MATERIALS AND METHODS**

A total of 94 from 232 patients were enrolled in this observational study. The data were taken retrospectively from medical record in tertiary care referral hospitals in Yogyakarta that capable of ophthalmic-oncology surgery by trained ocular-oncologist (FIGURE 1). All patients were diagnosed with eyelid tumor from January 2014 until December 2017 by histopathological examination. A total of 138 patients with ophthalmic lesions other than eyelid lesions were excluded from the study. We recorded the age, sex, tumor location at the eyelid, laterality, histopathological diagnosis of the lesions and different surgical procedure used in the treatment. This study was approved by The Medical and Health Research Ethics Committee (MHREC), Faculty of Medicine, Public Health and Nursing, Universitas Gadjah Mada.

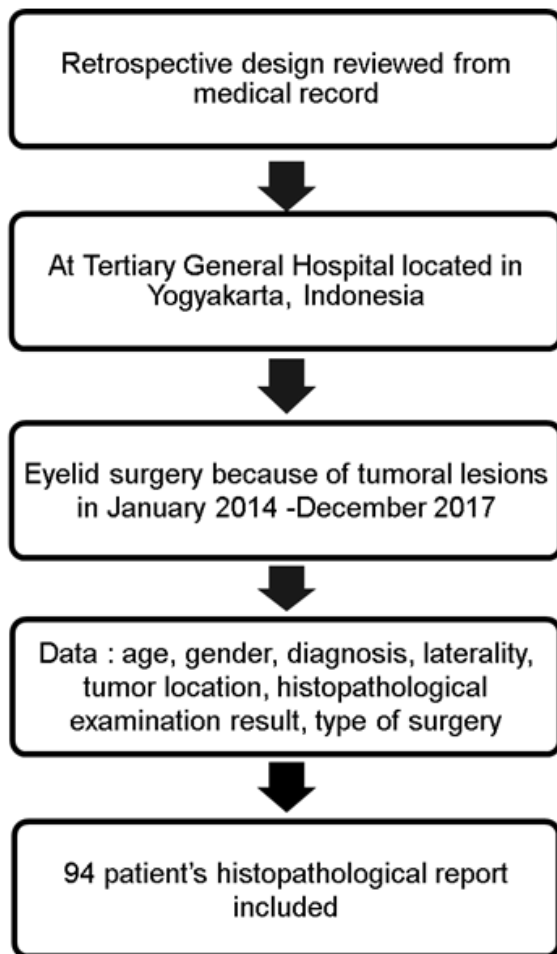


FIGURE 1. Research timetable

## RESULTS

Among subjects involved in this study, males were found to be more affected than females (59.6% vs 40.4%). There is no difference in laterality (OD 45.7% vs OS 54.3%) was found (TABLE 1). The highest prevalence of eyelid lesions i.e., 18 (19.1%) was observed in the age group of 61-70 years, which was followed

by 17 (18.1%) eyelid lesions in 51-60 years of age group. The lowest prevalence of eyelid lesions i.e., 4 (4.2%) was in the age group less than 11 years. Eyelid lesions were more common in upper eyelids (60.6%) as compared to the lower eyelids (39.4%). We also found that malignant lesions were more common than benign lesions in eyelid. Benign lesions were common in children and adults, whereas malignant lesions were common in the patients aged 50 years or more.

TABLE 1. Patient's characteristic

Characteristics	Number of cases (%)
Gender	
• Female	56 (59.6)
• Male	38 (40.4)
Age (years)	
• < 11	4 (4.3)
• 11 – 20	11 (11.7)
• 21 – 30	10 (10.6)
• 31 – 40	6 (6.4)
• 41 – 50	8 (8.5)
• 51 – 60	17 (18.1)
• 61 – 70	18 (19.1)
• 71 – 80	14 (14.9)
• > 80	6 (6.4)
Laterality	
• Right eye	43 (45.7)
• Left eye	51 (54.3)
Tumor location	
• Upper eyelid	57 (60.6)
• Lower eyelid	37 (39.4)

Each decade of age showed different pattern of eyelid tumor types. The distribution data of tumor types according to age were shown (FIGURE 2). Among all group of age, malignant lesions only distribution were shown in the > 81 groups of age.

### Distribution Data of Eyelid Tumor Types and The Age




FIGURE 2. Distribution data of malignancy types and the age

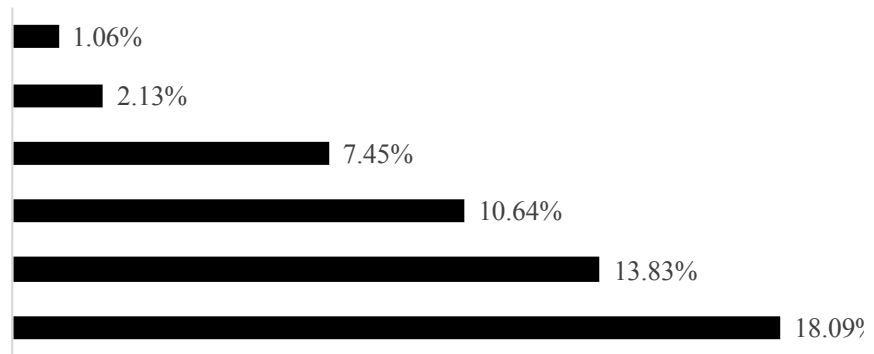


FIGURE 3. Distribution of malignant lesions

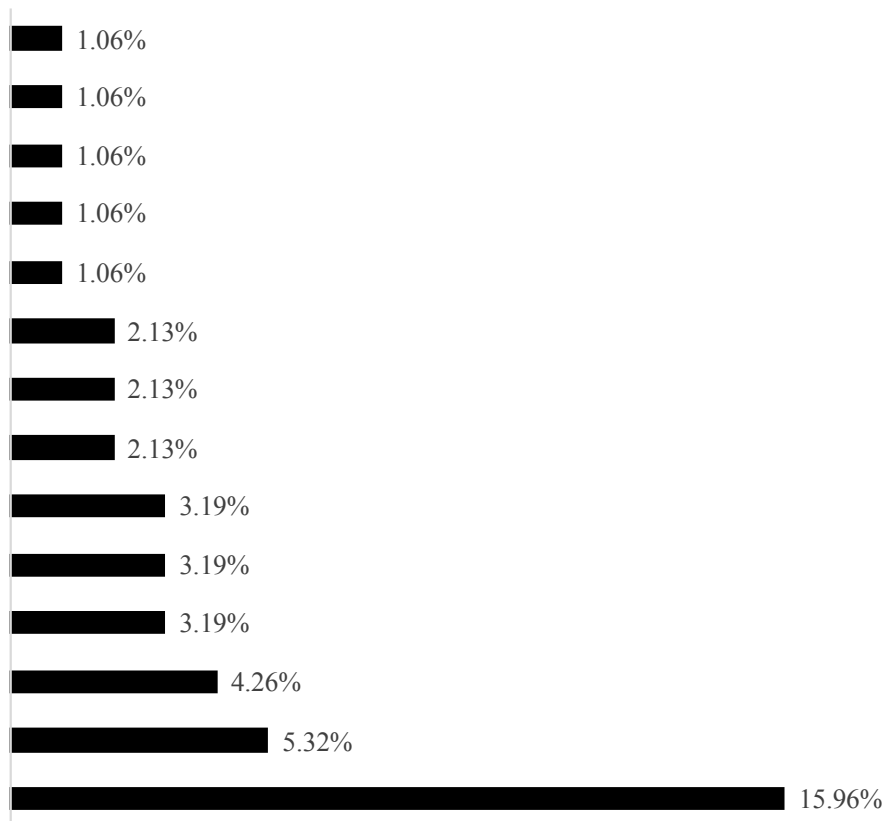


FIGURE 4. Distribution of benign lesions

Among malignant lesions, the highest prevalence was shown in sebaceous carcinoma 18 (18.09%) patients, followed by squamous cell carcinoma (SCC) 13 (13.83%), basal cell carcinoma (BCC) 10 (10.64%), non-hodgkin lymphoma

7 (7.45%), malignant melanoma 2 (2.13%) and spindle cell tumor 1 (1.06%) (FIGURE 3). In the other hand, the highest prevalence in benign eyelid lesions were found as an inflammation only 15 (15.96%) patients, followed by

epidermoid cyst 5 (5.32%), and the lowest prevalence were seborrhic keratosis, schwannoma, xanthelasma, dermoid

cyst, and chondroid syringoma which only found in 1 (1.1%) patient (FIGURE4).

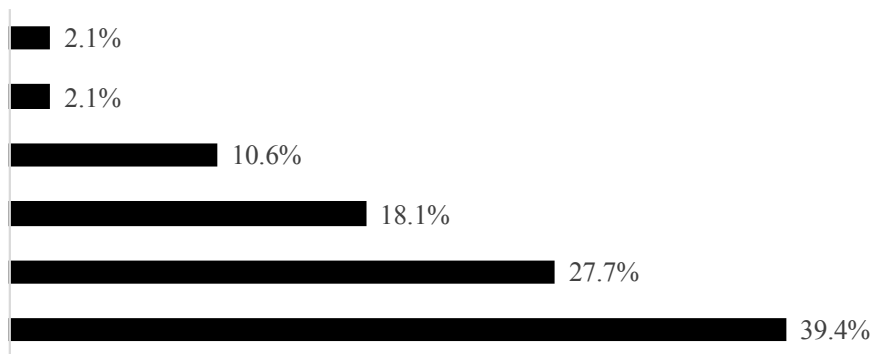


FIGURE 4. Distribution of surgical procedure for eyelid tumor

The location of the eyelid tumor was distributed in left upper eyelid 33 (35.11%), followed by right upper eyelid 24 (25.53%), right lower eyelid 19 (20.21%), and left lower eyelid 18 (19.15%). The therapy was varied from extirpation and biopsy (39.4%), wide excision (27.7%), excision and biopsy (18.1%), exenteration (10.6%), and also anterior and lateral orbitotomy (2.1%) for each procedure.

## DISCUSSION

The occurrence of malignant lesions on this study was found higher than benign lesions, and majority was presented at the sixth decade of life. This probably due to the length of exposure to the causal agents or the failure of surveillance mechanism from a DNA that leads to development of malignant lesion. Our study showed a similar result to the study of Paul *et al.* and Coroi *et al.* the most affected age range was the sixth decade.<sup>5,13</sup> In contrary, the study of Anandani *et al.* showed a different result, which found that the prevalence of benign lesions of the eyelids was higher than malignant lesion.<sup>10</sup>

This study showed males were found to be more affected than females (59.6% vs. 40.4%). This result similar to the study of Anandani *et al.* in which males were found to be more affected than females (57.82% vs. 42.18%).<sup>10</sup> Meanwhile, the study of Paul *et al.* showed that females were more affected than males (53% vs. 47%).<sup>13</sup> In this study, left upper eyelid (35.11 %) was the most common involved region when compared to right lower eyelid (20.21%). Other study showed varied result and reported that the common predilection of eyelid tumor was at right upper eyelid, left upper eyelid and lower eyelids.<sup>5,10,13</sup> This result may vary between studies due to the type of tumor, risk factor, and race variance. In the present study, SCC was more common than BCC, unlike others in which BCC was more common than SCC. A particular study showed that the occurrence of BCC is most common in lower lid whereas, SCC is more common than BCC in upper lid.<sup>14</sup> In contrast to other study, our previous study showed that most of BCC were found in lower eyelid.<sup>15</sup> Several studies showed that the eyelid malignancy incidence was increased in patients aged > 50 years.<sup>16-18</sup>

Concordantly, in our study all malignancy was found significantly higher in the in patients aged > 50 years.

In the present study, we also found that SGC was the most common malignancy among all malignant tumours. Concordantly, the study of Gupta *et al.* sebaceous gland carcinoma was more common in North India as compared to BCC and SCC while in the studies undertaken by Anandani *et al.*, SCC was the commonest one.<sup>10,16</sup>

## CONCLUSION

This study found that the eyelid tumor in Yogyakarta Special Region was majority found in male patient, presented at age of 60-70 years, and commonly located at superior eyelid. Histopathological result showed most cases were inflammation for benign lesion and sebaceous carcinoma for malignant lesion. Extirpation and biopsy were the most frequent surgical procedure approach found in this study.

## ACKNOWLEDGEMENTS

We would like to thank all the patients who contributed to this study, and also all those who helped in the collection of data until the study was completed.

## REFERENCES

1. Silverman N, Shinder R. What's New in Eyelid Tumors. *Asia Pac J Ophthalmol* 2017;6(2):143-52.
2. Ho M, Liu DT, Chong KK, Ng H, Lam DS. Eyelid tumours and pseudotumours in Hong Kong: a ten-year experience. *Hong Kong Med J* 2013;19(2):150-5. <https://doi.org/10.12809/hkmj134040>
3. Deprez M, Uffer S. Clinicopathological features of eyelid skin tumors. A retrospective study of 5504 cases and review of literature. *Am J Dermatopath*. 2009;31(3):256-62. <https://doi.org/10.1097/DAD.0b013e3181961861>
4. Pe'er J. Pathology of eyelid tumors. *Indian J Ophthalmol* 2016;64(3):177. <https://doi.org/10.4103/0301-4738.181752>
5. Coroi MC, Roșca E, Muțiu G, Coroi T, Bonta M. Eyelid tumors: histopathological and clinical study performed in County Hospital of Oradea between. *Rom J Morphol Embryo* 2010;51(1):111-5.
6. Yin VT, Merritt HA, Sniegowski M, Esmaeli B. Eyelid and ocular surface carcinoma: diagnosis and management. *Clin Dermatol* 2015;33(2):159-69. <https://doi.org/10.1016/j.clindermatol.2014.10.008>
7. Bagheri A, Tavakoli M, Kanaani A, Zavareh RB, Esfandiari H, Aletaha M, *et al.* Eyelid masses: A 10-year survey from a tertiary eye hospital in Tehran. *Middle East Afr J Ophthalmol* 2013;20(3):187. <https://doi.org/10.4103/0974-9233.114788>
8. Bălășoiu A, Mănescu M, Bălășoiu M, Avrămoiu I, Pirici I, Burcea M, *et al.* Histological and immunohistochemical study of the eyelid basal cell carcinomas. *Rom J Morphol Embryo* 2015;56(2 Suppl):803-10.
9. Mohan BP, Letha V. Profile of eye lid lesions over a decade: a histopathological study from a tertiary care center in South India. *Int J Adv Med* 2017;4(5):1406-11. <https://doi.org/10.18203/2349-3933.ijam20174293>
10. Anandani GM, Parikh SB, Shah NR. Histopathological Study of Eyelid Lesions. *Natl Lab Med* 2018;7(1):007-11.
11. Ford J, Thakar S, Thuro B, Esmaeli B. Prognostic value of the staging system for eyelid tumors in the 7<sup>th</sup> edition of the American Joint Committee on Cancer Staging Manual. *Ophthal Plast Reconstr Surg* 2017;33(5):317-24. <https://doi.org/10.1097/IOP.0000000000000901>
12. Yu S-S, Zhao Y, Zhao H, Lin J-Y, Tang

- X. A retrospective study of 2228 cases with eyelid tumors. *Int J Ophthalmol* 2018;11(11):1835-41.
13. Paul S, Vo DT, Silkiss RZ. Malignant and benign eyelid lesions in San Francisco: study of a diverse urban population. *Am J Clin Med* 2011;8(1):40-6.
14. Pawar S, Sharma R, Mahapatra A, Lad S, Musa M. Choroid plexus papilloma of the posterior third ventricle during infancy & childhood: report of two cases with management morbidities. *Neurol India* 2003;51(3):379.
15. Supartoto A, Indrakila S, Pardawan. Clinical aspect and management of basal cell carcinoma. *J Med Sci* 2004;36(3):167-71.
16. Gupta P, Gupta RC, Khan L. Profile of eyelid malignancy in a Tertiary Health Care Center in North India. *J Cancer Res Ther* 2017; 13(3):484.