

Neuroprotective effect of vitamin D₃ toward apoptosis induced by ethanol in CA1 pyramidal cells of rat hippocampus

Junaedy Yunus*, Djoko Prakosa, Dwi Cahyani Ratna Sari
Department of Anatomy, Faculty of Medicine, Universitas Gadjah Mada,
Yogyakarta, Indonesia

ABSTRACT

As an antioxidant, Vitamin D₃ can protect neurons from damage caused by oxidative stress. Ethanol is known to have neurotoxic effects by inducing an increase in oxidative stress. One of the brain regions that is most sensitive to neurotoxic effects induced by ethanol is hippocampus, especially its CA1 region. This study was aimed to determine the neuroprotective effects of vitamin D₃ in preventing the apoptosis in CA1 hippocampal pyramidal cells induced by ethanol. Fifteen male Wistar rats (*Rattus norvegicus*) were randomly divided into three groups. The control group was given daily normal saline solution intraperitoneally. The ethanol group was given 20% ethanol solution at a dose of 3 g/kg BW/day intraperitoneally. The vitamin D₃ group was given vitamin D₃ 1 µg/kg BW/day in 20% ethanol solution at a dose of 3 g/kg BW/day intraperitoneally. After 30 days, the rats were sacrificed, their brains were perfused with PBS followed by fixative and the hippocampus was dissected for histological preparations. Immunohistochemical staining for caspase was performed. Percentage of apoptotic CA1 hippocampal pyramidal cells was calculated. The results showed there was no significant difference ($p > 0.05$) on the total number of pyramidal cells between the control group (20.52 ± 1.31), the ethanol group (19.02 ± 1.60), and the vitamin D₃ group (21.06 ± 0.70) per field of view. However there was a significant increase ($p < 0.05$) in the percentage of apoptotic CA1 hippocampal pyramidal cells in the ethanol group ($16.09 \pm 0.67\%$) compared to the control group ($10.60 \pm 0.95\%$). Vitamin D₃ significantly ($p < 0.05$) prevented an increase in the percentage of apoptotic CA1 hippocampal pyramidal cells in the vitamin D₃ group ($10.82 \pm 0.64\%$). In conclusion, vitamin D₃ had a neuroprotective effect to prevent an increase in apoptosis in CA1 hippocampal pyramidal cells to the neurotoxic effects induced by ethanol.

ABSTRAK

Vitamin D₃ dapat berperan sebagai antioksidan untuk melindungi neuron dari kerusakan akibat stres oksidatif. Efek neurotoksik akibat stres oksidatif dapat diinduksi oleh etanol. Hippocampus, khususnya lapisan CA1, merupakan salah satu bagian otak yang paling rentan terhadap efek neurotoksik etanol. Tujuan penelitian ini adalah untuk mengkaji efek neuroprotektif vitamin D₃ untuk mencegah apoptosis sel piramidal di CA1 hippocampus terhadap efek neurotoksik yang diinduksi oleh etanol. Lima belas ekor tikus galur Wistar (*Rattus norvegicus*) jantan dibagi secara random ke dalam 3 kelompok perlakuan. Kelompok kontrol diberi larutan NaCl fisiologis secara intraperitoneal (IP). Kelompok etanol diberi larutan etanol 20% dengan dosis 3g/kgBB/hari secara IP. Kelompok vitamin D₃ diberi vitamin D₃ dosis 1 µg/kg BB/hari dalam larutan etanol 20% dengan dosis 3 g/kg BB/hari secara IP. Setelah perlakuan selama 30 hari, tikus diperfusi dan diambil bagian hippocampusnya untuk dijadikan preparat histologi. Kemudian dilakukan pengecatan imunohistokimia untuk penilaian persentase jumlah sel piramidal di CA1 hippocampus yang mengalami apoptosis. Hasil penelitian menunjukkan tidak ada perbedaan bermakna ($p > 0.05$) jumlah total sel piramidal antara kelompok kontrol ($20,52 \pm 1,31$), kelompok etanol ($19,02 \pm 1,60$), dan kelompok vitamin D₃ ($21,06 \pm 0,70$) per lapangan pandang. Namun terdapat

* corresponding author: jun10121@yahoo.com

peningkatan secara signifikan ($p < 0,05$) persentase piramidal di CA1 hippocampus yang mengalami apoptosis pada kelompok etanol ($16,08 \pm 0,65\%$) dibandingkan dengan kelompok kontrol ($10,61 \pm 0,94\%$). Pemberian vitamin D₃ secara signifikan ($p < 0,05$) dapat mencegah peningkatan persentase sel piramidal di CA1 hippocampus yang mengalami apoptosis pada kelompok vitamin D₃ ($10,82 \pm 0,62\%$). Dengan demikian dapat disimpulkan bahwa vitamin D₃ memiliki efek neuroprotektif untuk mencegah peningkatan apoptosis sel piramidal di CA1 hippocampus terhadap efek neurotoksik yang diinduksi oleh etanol.

Keywords: vitamin D₃ – ethanol – apoptosis – CA1 hippocampus – caspase-3

INTRODUCTION

Vitamin D₃, a fat-soluble vitamin, is metabolized in the body into an active form which has various biological effects, including its classical effect as a regulator of calcium metabolism.¹ Other various non-classical effects of vitamin D₃ has been widely reported, including as regulator of hormone secretion, immune responses, and cellular proliferation and differentiation.² Vitamin D₃ is also reported to act as a membrane antioxidant that protects neurons from damage caused by oxidative stress.³

Vitamin D₃ accumulates in cell membranes and decreases lipid peroxidation.⁴ Lin *et al.*⁵ showed that vitamin D₃ has a neuroprotective effect against zinc-induced apoptosis in the substantia nigra. Moreover, Landfield and Cadwallader-Neal⁶ reported that long-term treatment with calcitriol (1,25-dihydroxy-vitamin D₃) inhibit decrease in neuronal density of hippocampal CA1 in aging rats. Sardar *et al.*⁷ mentioned that vitamin D₃ may function as an antioxidant. It is assumed that its effectiveness is higher than that observed with vitamin E supplementation.

Apoptosis that is mediated by the increased oxidative stress can be induced by various types of inducers, such as pathophysiologic conditions, physiologic stimuli, pesticides, drugs, and others.⁸ Alcohol or ethanol is one of the compounds that has been widely known to cause neurotoxic effects that can induce

apoptosis of brain neurons due to increased oxidative stress.⁹

Eventhough excessive consumption of alcohol has been reported for a long time to cause permanent organ damage or even death, alcohol beverages are still widely consumed worldwide.¹⁰ According to WHO,¹¹ for the last 40 years, alcohol consumption per capita for adult population older than 15-year-old in Indonesia tends to increase. In 1961, the level of alcohol consumption was equal to 0.02 liter, and in 2001 increased 5 times as much, estimated to be 0,1 liter.¹¹

Many studies demonstrated neurotoxic effects of alcohol on the central nervous system, either in adult or developing fetal.¹² Damage of the adult brain caused by alcohol results in cognitive deficits such as learning and memory impairment.¹³ Meanwhile, alcohol consumption during pregnancy and lactation period can lead to fetal brain dysfunction by inducing apoptosis of brain neurons.^{10,14} The mechanisms by which alcohol induces neuronal apoptosis are not well understood.¹⁰ Several studies have examined the role of oxidative stress on alcohol-mediated neurotoxicity, possibly via the formation of free radicals that leads to cellular damage and death.^{9,15}

Due to its low concentration of antioxidant, brain tissue is susceptible to damage induced by oxidative stress. Hippocampus and cerebellum are regions in the brain most susceptible to damage induced by oxidative stress.¹⁶

Narwanto¹⁷ reported that a significant decrease in the number of pyramidal cells in CA1 hippocampus occurred after ethanol administration. Several studies have shown that antioxidant supplementation may reduce the neurotoxic effects of ethanol.^{9,10} Neuroprotective effects of vitamin D₃ toward neuronal damage caused by ethanol-induced oxidative stress need further investigation to reveal the role of vitamin D₃ as an antioxidant. The aim of this study was to evaluate whether vitamin D₃ could prevent apoptosis of pyramidal cells in rats hippocampal CA1 induced by ethanol.

MATERIALS AND METHODS

Animals

Fifteen adult male Wistar rats (*Rattus norvegicus*), two-month-old, weighed \pm 200 g, were used in this study. The animals were acquired from Department of Pharmacology and Therapy, Faculty of Medicine, Gadjah Mada University, Yogyakarta. All animals were housed in cages with the size of 40 x 30 x 15 cm³ and covered with woven wire. Each cage contained one rat. Food and water were available *ad libitum*. The study was approved by the Medical and Health Research Ethics Committee, Faculty of Medicine, Universitas Gadjah Mada, Yogyakarta.

Treatments

After an adaptation period of 7 days, the animals were randomly divided into three groups: control, ethanol, ethanol and vitamin D₃ groups. Each group consisted of 5 rats. The control group received normal saline solution daily. Ethanol group received 20% ethanol (3 g/kg BW) once a day. Ethanol and vitamin D₃ group received ethanol plus vitamin D₃ (Calcitriol, Merck-Darmstadt, Germany; 1 μ g/kg BW) once daily, administered intraperitoneally. Vitamin D₃ was diluted in 20% ethanol;

so that the solution contained 1 μ g of vitamin D₃ per ml. The treatments were given intraperitoneally for 30 days. For dosage calculation, rat body weight was measured once for every other day.

Sampel preparation

On the 31st day, all rats were sacrificed. Rats were anesthetized with chloroform and then transcardially perfused with PBS solution for 10 minutes, followed by 4% formaldehyde solution for 20 minutes. Decapitation was performed and the brain was immediately removed and fixed in 4% formalin solution. Paraffin blocks of brain tissue were made based on the rat stereotaxic map by lifting the region containing the hippocampus by cutting the rat brain in the coronal plane with a distance of -3.80 mm from bregma.

Assessment of apoptosis

The paraffin blocks were serially sectioned in the coronal plane. The thickness of each section was 4 μ m. Four consecutive sections with the distance of 100 μ m from one another were collected from each brain. Then immunohistochemical staining was performed using antibody Anti-ACTIVE[®] Caspase-3 pAb (Promega). Tissue sections were deparaffinized by immersing them in xylene and then rehydrated through a graded series of ethanol solutions. Subsequently, the slides were washed in PBS/Triton[®] X-100 0.2% and PBS solution.

The next process were blocking with Background Sniper (Biocare) and then incubating them with primary antibody Anti-ACTIVE[®] Caspase-3 pAb (Promega). After washed in PBS/Tween[®] 20 0.1% and PBS solution, the slides were incubated with secondary antibody Trekkie Universal Link (Biocare). Then streptavidin, that had been labeled with a peroxidase enzyme, and 1,3-

diaminobenzidin (DAB) substrate were added and counterstained using hematoxylin staining. Furthermore, the slides were washed and dehydrated through a grade series of ethanol solutions. On the cover slip mounting media was given and then placed on a glass object.

After dried, the slides were observed under a light microscope using 400x magnifications, and then apoptotic pyramidal cells in CA1 hippocampus were determined by counting them in each section per 25 fields of view. The number of apoptotic pyramidal cells was presented as percentage (%).

Statistical analysis

The data were presented as mean \pm SD. The quantitative data on the percentage of pyramidal cells (ratio scale) were statistically analyzed by the one-way ANOVA, followed by Tukey HSD as a post hoc analysis and $p < 0.05$ was accepted as statistically significant. All calculations of statistical analysis used SPSS version 18 for Windows.

RESULTS

On examination by light microscope, there were no significant differences in morphologic appearance in CA1 hippocampal pyramidal cells, either normal or apoptotic cells, among the three groups. Using hematoxylin counterstaining, the substantia Nissl and the nucleoli looked dark purple-blue, the cell nuclei looked blue-transparent in CA1 hippocampal pyramidal cells, with no background color. Whereas pyramidal cells which undergoing apoptosis (expressing active caspase-3) by immunohistochemical staining with antibody Anti-ACTIVE® Caspase-3 pAb (Promega) looked brown on their cell nuclei (FIGURE 1).

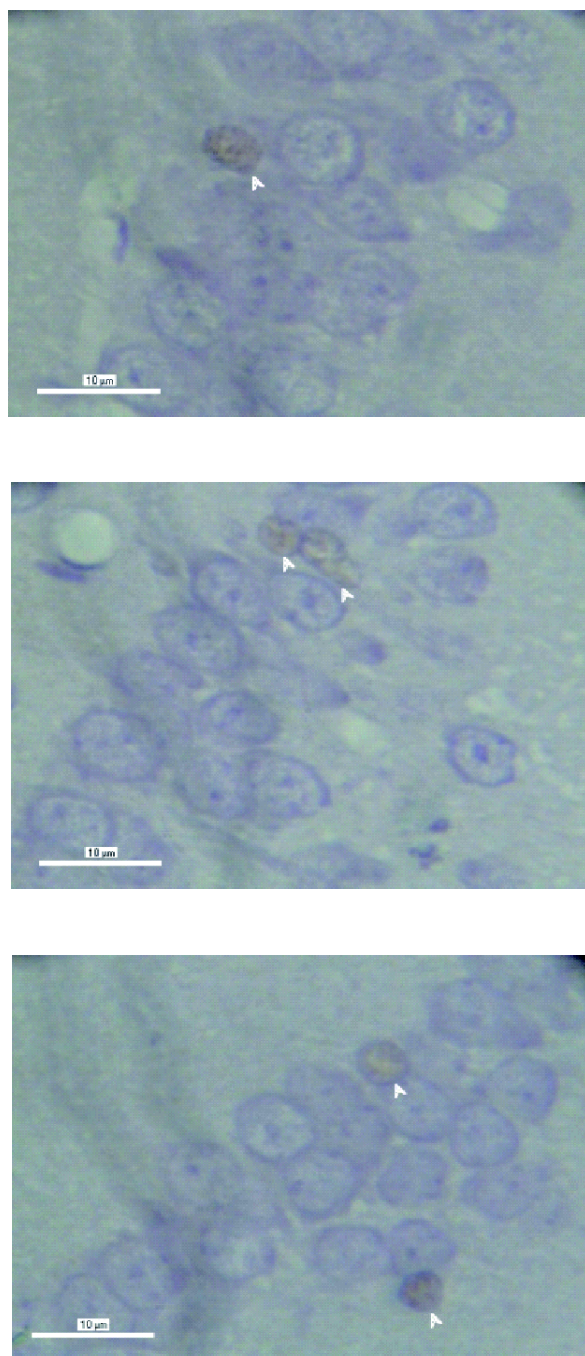


FIGURE 1. CA1 hippocampal pyramidal cells. Immunohistochemical staining with antibody Anti-ACTIVE® Caspase-3 pAb (Promega), the cells which undergoing apoptosis looked brown, 400x magnification, A: control group, B: ethanol group, C: vitamin D₃ group

The results of this study showed that the average total number of CA1 hippocampal pyramidal cells per field of view in the control, ethanol and vitamin D₃ groups were 20.52 ± 1.31 , 19.02 ± 1.60 , and 21.06 ± 0.70 , respectively (FIGURE 2). There was no significant difference found among the three groups ($p > 0.05$).

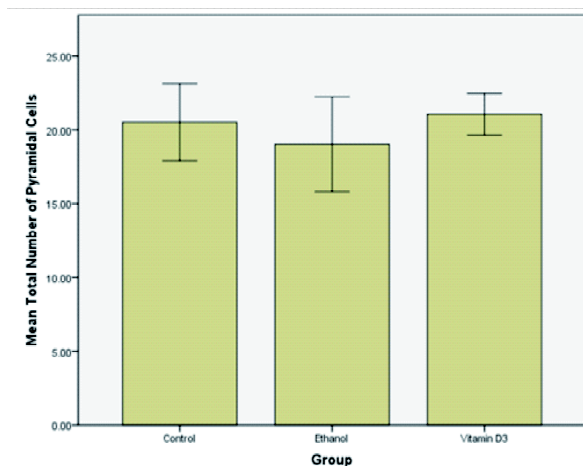


FIGURE 2. The total number of pyramidal cells in the CA1 hippocampus per field of view (mean ± SD).

The average percentage of CA1 hippocampal pyramidal cells which undergoing apoptosis per field of view in the control, ethanol and vitamin D₃ group were $10.61 \pm 0.94\%$, $16.08 \pm 0.65\%$, and $10.82 \pm 0.62\%$ respectively (FIGURE 3). These results showed that the percentage of pyramidal cells which undergoing apoptosis in the ethanol group was greater than the control group and vitamin D₃. It was found that there was a significant difference in the percentages of CA1 pyramidal cells between the ethanol group with the control group and vitamin D₃ ($p < 0.05$).

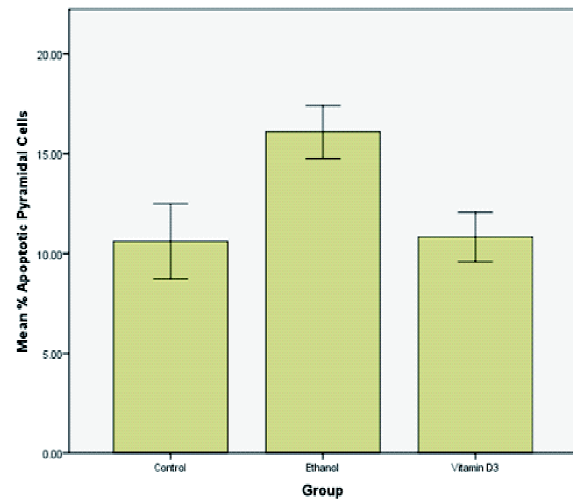


FIGURE 3. The percentage of pyramidal cells which undergoing apoptosis in the CA1 hippocampus per field of view (mean ± SD)

DISCUSSION

No significant difference in the average total number of CA1 hippocampal pyramidal cells among the three groups was observed in this study. This result showed that ethanol administration at a dose of 3 g/kg/day for 30 days did not lead to a decrease in the average number of pyramidal cells per field of view in the CA1 hippocampus.

These results were inconsistent with the previous study reported by Narwanto¹⁷ that showed a decrease in the number of CA1 hippocampal pyramidal cells after ethanol administration by intraperitoneal injection at a dose of 3 g/kg/day for 30 days. Lundqvist *et al.*¹⁸ also reported that ethanol administration intraperitoneally at a dose of 3 g/kg/day for 30 days caused a significant decrease in the number of pyramidal cells in CA2-CA3 hippocampus. Moreover, Lukoyanov *et al.*¹⁹ showed a significant decrease in the number of pyramidal cells in CA1 (18%) and CA3 (19%) hippocampus induced by ethanol orally with an average dose of 7.5 g/kg/day for 13 months.

Several possibilities could explain the differences in the results of this study. The first possibility is the duration of ethanol exposure. Renis *et al.*²⁰ demonstrated that a number of biochemical alterations was a consequence of ethanol administration. Several changes occurred immediately after exposure to ethanol, such as intracellular decreases in GSH concentration and partial inactivation of respiratory chain complexes. Potential targets such as nuclear and mitochondrial DNA belong to the category of cytological or subcellular structures which require longer exposure times to the oxidative effects of ethanol. While the study by Franke *et al.*²¹ mentioned that ethanol administration for 4 weeks did not cause a significant change in the total number of neurons compared to control groups, there was an increasing number of pyramidal and granular cells that were damaged.

The second possibility is related to the method for counting the number of pyramidal cells in CA1 hippocampus. In this study the average total number of pyramidal cells per field of view was obtained from the calculation at 25 fields of view of 4 sections with a thickness of 4 μm and distance between sections of 100 μm . Narwanto¹⁷ used the calculation of average total number of pyramidal cells per field of view from 3 sections of preparations with a thickness of 4 μm and distance between sections of 10 sections (= 40 μm). While Shirpoor *et al.*¹⁰ used the calculation from 10 sections with a thickness of 5 μm and distance between sections of 10 sections (= 50 μm). Currently, one of the methods that are considered more valid to obtain the estimation of total number of neurons in the hippocampal region is the stereology method, which one of its newest methods is optical fractionator. From the current methods, it will be obtained unbiased estimation of total number of neurons.²² This research did not use such methods because of limited fund

and quantity of the primary antibody used for immunohistochemical staining, considering the optical fractionator method takes about 18-22 sections for each sample.²³

Another possibility that could explain the differences in these results is that there are differential vulnerabilities within CA1 pyramidal cell layer through the dorsal-ventral plane. This would explain findings from previous reports that had targeted a specific region rather than the entire extent of the hippocampal formation.²³

This study showed that the percentage of pyramidal cells which undergoing apoptosis in the ethanol group was greater than the control group and vitamin D₃. This result was consistent with previous study by Shirpoor *et al.*¹⁰ that showed a significant increase in the percentage of apoptotic hippocampal cells in all layers of the hippocampus, including CA1, CA2, CA3, and gyrus dentatus after ethanol administration by subcutaneous injection for 35 days (14 days prenatal and 21 days postnatal).

In the control group it was obtained that the percentage of pyramidal cells in CA1 hippocampus which undergoing apoptosis was 10.61%. This result showed that even normal hippocampal neurons also underwent apoptosis. Ferrer *et al.*²⁴ reported apoptosis rates of about 7-8% in the rat hippocampus during the early postnatal period. This study found a higher apoptosis rates. This can be explained by study of Engelmann *et al.*²⁵ who reported that the treatments on the Morris water maze were a form of stressor for the animals.

The mechanisms of ethanol that can induce apoptosis of brain neurons are not well understood.¹⁰ Three possibilities should be considered to explain the neurotoxic effects of ethanol. First, the lipid-soluble properties of ethanol have biological effects that can physically denature or disaggregate cellular macromolecules (e.g., mitochondria, reticulum

endoplasmikum, etc.). Second, the cytotoxic effects of ethanol are linked to its metabolic fate and are most probably mediated by the formation of free radicals via oxidative metabolic pathways of ethanol.^{9,15} Ethanol can increase ROS formation by inducing cytochrome p4502E1 (CYP2E1), which is widely distributed in brain tissue.²⁶ Third, the cytotoxic effects of ethanol result from a combined influence of its physical properties, chemical, and metabolic properties.²⁰ In physiologic conditions, intracellular antioxidants will convert free radicals into compounds that are not harmful to the cells so it can protect the cells from damage induced by free radicals.²⁷ Low concentrations of antioxidants causes brain tissue to be susceptible to damage induced by oxidative stress. Chronic ethanol administration has been proven to be able to reduce the level of antioxidant enzymes, e.g. glutathione peroxidase, and interfere with glutathione homeostasis.²⁸ Hippocampus and cerebellum are regions of the brain which are most susceptible to damage induced by oxidative stress, because those regions have lower antioxidant activities.¹⁶ The failure of protection mechanisms of antioxidants due to excessive production of free radicals and decrease in the activity of scavenger enzymes cause lipid peroxidation which leads to cellular damage or death. This is proved by Shirpoor *et al.*¹⁰ that showed significant increase in levels of lipid hydroperoxide and protein carbonyls in the hippocampus and cerebellum induced by ethanol compared to control group.

Using one-way ANOVA statistical test followed by Tukey HSD as a post hoc analysis, it was found that there was a significant difference in the percentages of CA1 pyramidal cells which undergoing apoptosis between vitamin D₃ group and ethanol group, whereas between vitamin D₃ group and control group obtained result of no significant difference in the percentages of CA1 pyramidal cells which

undergoing apoptosis. The results are consistent with the study by Lin *et al.*⁵ that showed vitamin D₃ administration at a dose of 1 µg/kg/day had neuroprotective effects against apoptosis induced by zinc in the substantia nigra. While Landfield and Cadwallader-Neal⁶ showed that long-term treatment with calcitriol (1,25-dihydroxy-vitamin D₃) inhibits decrease in CA1 hippocampal neuronal density due to aging process.

The mechanisms of vitamin D₃ that can reduce the neurotoxic effects induced by oxidative stress may be explained by the following three mechanisms. First, the protective effects of antioxidants to oxidative stress induced by ethanol may be derived from the modulation of expression of survival-promoting molecules, e.g. from bcl-2 gene family. Several studies have shown that survival-promoting proteins, e.g. Bcl-2 and Bcl-xl, play a role in antioxidant pathway to inhibit apoptosis, and even over-expression of these proteins can inhibit the oxidation process, e.g. lipid peroxidation.²⁹ Vitamin D₃ has been reported to play a role in upregulation of neurotrophic factors, such as GDNF (glial cell-derived neurotrophic factor), which can prevent brain damage caused by the ischemic process and neurotoxicity induced by oxidative stress.⁵ Ibi *et al.*³⁰ reported that vitamin D₃ did not play role directly as a scavenger of free radicals, but rather induces the synthesis of proteins that provide neuroprotection effect against the cytotoxic effects induced by ROS.

Various physiological effects of vitamin D₃ are mediated by VDR.³⁰ VDR are localized in pyramidal and granular cell layers in CA1, CA2, CA3, and gyrus dentatus. The interaction between vitamin D₃ and its receptor stimulates the synthesis of neurotrophic factors involved in neuroprotective process in the central nervous system.³¹ Current *in vitro* studies also show vitamin D₃ increases intracellular glutathione

content and can protect dopaminergic neurons against the effects of glutamate ROS neurotoxicity on the mesencephalic culture.³⁰

Second, vitamin D₃ acts as a membrane antioxidant that protects neurons against damage caused by oxidative stress.³ Vitamin D₃ accumulates in the cell membrane and reduces lipid peroxidation.⁴ Several studies have mentioned that the antioxidant function of vitamin D₃ may be more potent than vitamin E, melatonin, and estrogen.^{5,7} Third, vitamin D₃ has a protective effect by regulating Ca²⁺ homeostasis in brain cells. Vitamin D₃ is known to affect the taking of Ca²⁺ in some inducible cells and to modulate voltage-sensitive Ca²⁺ channel. This is proved in studies with culture of hippocampal neurons, in which vitamin D₃ can have a strong neuroprotective effect against glutamate-mediated cytotoxicity.⁶

Therefore, further studies on the mechanism of action of vitamin D₃ in neurons are still needed. Thus, vitamin D₃ can be developed into one of the more potent antioxidant alternatives to prevent the degenerative effects induced by toxic compounds, such as ethanol and other oxidants.

CONCLUSION

It can be concluded that vitamin D₃ at a dose of 1 µg/kg/day has a protective effect to prevent an increase apoptosis in CA1 hippocampal pyramidal cells in male Wistar rats (*Rattus norvegicus*) induced by ethanol at a dose of 3 g/kg/day for 30 days.

Further experimental studies will be performed to evaluate neuroprotective effects of vitamin D₃ to the neurotoxic effects induced by ethanol on infant rats (prenatal and postnatal periods), the function of spatial working memory, and the involvement of other brain parts which are also more susceptible to neurotoxic effects, such as the cerebellum.

ACKNOWLEDGEMENTS

We would like to thank all technicians from Department of Anatomy, Faculty of Medicine, Universitas Gadjah Mada for all of the supports during this study.

REFERENCES

1. Feldman D, Malloy PJ, Gross C. Vitamin D: biology, action, and clinical implications. In: Marcus R, Feldman D, Nelson DA, Rosen CJ, editors. Osteoporosis, 2nd ed. San Diego: Elsevier Academic Press, 2001.
2. Bikle D. Nonclassic actions of vitamin D. J Clin Endocrinol Metab 2009; 94(1):26-34.
3. Wiseman H. Vitamin D is a membrane antioxidant: ability to inhibit iron-dependent lipid peroxidation in liposomes compared to cholesterol, ergosterol and tamoxifen and relevance to anticancer action. FEBS Lett 1993; 326(1-3):285-8.
4. Sardar S, Singh M. Vitamin D₃ as a modulator of cellular antioxidant defence in murine lymphoma. Nutr Res 2000; 20(1):91-102.
5. Lin AMY, Fan SF, Yang DM, Hsu LL, Yang CHJ. Zinc-induced apoptosis in substantia nigra of rat brain: neuroprotection by vitamin D₃. Free Radic Biol Med 2003; 34(11):1416-25.
6. Landfield PW, Cadwallader-Neal L. Long-term treatment with calcitriol (1,25(OH)₂ vit D₃) retards a biomarker of hippocampal aging in rats. Neurobiol Aging 1998; 19(5): 469-77.
7. Sardar S, Chakraborty A, Chatterjee M. Comparative effectiveness of vitamin D₃ and dietary vitamin E on peroxidation of lipids and enzymes of the hepatic antioxidant system in Sprague-Dawley rats. Internat J Vitam Nutr Res 1996; 66(1):39-45.
8. Kannan K, Jain SK. Oxidative stress and apoptosis. Pathophysiology 2000; 7(3):153-63.
9. Heaton MB, Mitchell JJ, Paiva M. Amelioration of ethanol-induced neurotoxicity in the neonatal rat central nervous system by antioxidant therapy. Alcohol Clin Exp Res 2000; 24(4):512-8.
10. Shirpoor A, Minassian S, Salami S, Khadem-Ansari MH, Ghaderi-Pakdel F, Yeghiazaryan M. Vitamin E protects developing rat hippocampus and cerebellum against ethanol-induced oxidative stress and apoptosis. J Food Chem 2008; 113(1):115-20.

11. World Health Organization. WHO global status report on alcohol 2004. Geneva: World Health Organization, 2004. Available from URL: http://www.searo.who.int/LinkFiles/Alcohol_and_Substance_abuse_Indonesia.pdf.
12. Diamond I, Messing RO. Neurologic effects of alcoholism. *West J Med* 1994; 161(3):279-87.
13. Butterfield DA, Howard B, Yatin S, Koppal T, Drake J, Hensley K, et al. Elevated oxidative stress in models of normal brain aging and Alzheimer's disease. *Life Sci* 1999; 65(18-19): 1883-92.
14. Maier SE, West JR. Alcohol and nutritional control treatments during neurogenesis in rat brain reduce total neuron number in locus coeruleus, but not in cerebellum or inferior olive. *Alcohol* 2003;30(1):67-74.
15. Chen SY, Sulik KK. Free radical and ethanol-induced cytotoxicity in neural crest cells. *Alcohol Clin Exp Res* 1996; 20(6):1071-6.
16. Henderson GI, Chen JJ, Schenker S. 1999. Ethanol, oxidative stress, reactive aldehydes, and the fetus. *Front Biosci* 1999; 4:D541-50.
17. Narwanto MI. Pengaruh pemberian etanol secara kronik terhadap jumlah sel piramidal di CA1 dan CA3 hippocampus dan memori kerja spasial pada tikus (*Rattus norvegicus*) remaja [Thesis]. Yogyakarta: Universitas Gadjah Mada, 2008.
18. Lundqvist C, Alling C, Knoth R, Volk B. Intermittent ethanol exposure of adult rats: hippocampal cell loss after one month of treatment. *Alcohol* 1995; 30(6):737-48.
19. Lukoyanov NV, Madeira MD, Paula-Barbosa MM. Behavioral and neuroanatomical consequences of chronic ethanol intake and withdrawal. *Physiol Behav* 1999; 66(2):337-46.
20. Renis M, Calabrese V, Russo A, Calderone A, Barcellona ML, Rizza V. Nuclear DNA strand breaks during ethanol-induced oxidative stress in rat brain. *FEBS Lett* 1996; 390(2):153-6.
21. Franke H, Kittner H, Berger P, Wirkner K, Schramek J. The reaction of astrocytes and neurons in the hippocampus of adult rats during chronic ethanol treatment and correlations to behavioral impairments. *Alcohol* 1997; 14(5):445-54.
22. West MJ, Slomianka L, Gundersen HJ. Unbiased stereological estimation of total number of neurons in the subdivisions of the rat hippocampus using optical fractionator. *Anat Rec* 1991; 231(4):482-97.
23. Tran TD, Kelly SJ. Critical periods for ethanol-induced cell loss in the hippocampal formation. *Neurotoxicol Teratol* 2003;25(5):519-28.
24. Ferrer I, Serrano T, Soriano E. Naturally occurring cell death in the subicular complex and hippocampus in the rat during development. *Neurosci Res* 1990; 8(1):60-6.
25. Engelmann M, Ebner K, Landgraf R, Wotjak CT. Effects of Morris water maze testing on the neuroendocrine stress response and intrahypothalamic release of vasopressin and oxytocin in the rat. *Horm Behav* 2006; 50(3):496-501.
26. Montoliu C, Sancho-Tello M, Azorin I, Burgal M, Valles S, Renau-Piqueras J, et al. Ethanol increases cytochrome P4502E1 and induces oxidative stress in astrocytes. *J Neurochem* 1995; 65(6):2561-70.
27. Hunt JV, Smith CC, Wolf SP. Autooxidative glycosylation and possible involvement of peroxides and free radicals in LDL modification by glucose. *Diabetes* 1990; 39(11):1420-4.
28. Coleman MD, Eason CR, Bailey JC. The therapeutic use of lipoic acid in diabetes: a current perspective. *Environ Toxicol Pharmacol* 2001; 10(4):167-72.
29. Hockenbery H, Oltvai Z, Yin X, Millman C, Korsmeyer S. Bcl-2 functions in an antioxidant pathway to prevent apoptosis. *Cell* 1993; 75(2):241-51.
30. Ibi M, Sawada H, Nakanishi M, Kume T, Katsuki H, Kaneko S, et al. Protective effects of 1 alpha, 25-(OH)(2)D(3) against the neurotoxicity of glutamate and reactive oxygen species in mesencephalic culture. *Neuropharmacology* 2001; 40(6):761-71.
31. Langub MC, Herman JP, Malluche HH, Koszewski NJ. Evidence of functional vitamin D receptors in rat hippocampus. *Neuroscience* 2001; 104(1):49-56.